Clinical Advances in
HEMATOLOGY & ONCOLOGY™
A Peer-Reviewed Journal

December 2010 www.clinicaladvances.com Volume 8, Issue 12, Supplement 22

Discussants

James O. Armitage, MD
Professor, Internal Medicine
Oncology/Hematology Division
University of Nebraska
Medical Center
Omaha, Nebraska

Eric D. Hsi, MD
Professor, Pathology
Department of Clinical Pathology
Cleveland Clinic Lerner
College of Medicine
Cleveland, Ohio

Francine M. Foss, MD
Professor of Medicine
Hematology and LLM Program
Yale Medical Oncology
New Haven, Connecticut

T-cell Lymphoma: Therapeutic Overview and Disease State Awareness

Abstract

T-cell lymphomas comprise a heterogeneous group of lymphoproliferative disorders that include approximately 10–15% of all lymphomas, and there is a geographic variation in their frequency. With the exception of a few subtypes that are associated with a more indolent course, the majority of T-cell lymphomas are aggressive in nature. Patients with peripheral T-cell lymphomas (PTCL) have an especially poor prognosis, due both to the aggressive disease course as well as the lack of effective treatments. A number of PTCL subtypes have now been defined, although the histologic, immunologic, and cytogenetic distinctions between some subtypes are subtle. Proper diagnosis of the PTCL subtype is important, as each subtype is associated with a varying prognosis and thus may be treated differently. There is no true standard of care for PTCL, and this aggressive disease has historically been treated with therapeutic regimens designed for B-cell lymphomas, such as the cyclophosphamide, doxorubicin, vincristine, and prednisone (CHOP) regimen. However, studies now show that these regimens are not optimal for most patients with PTCL. Therefore, recent efforts have focused on the development of therapeutic regimens designed to be more effective in PTCL, some of which are specifically targeted against T-cell markers. A number of these agents now show promise in the treatment of both frontline and relapsed/refractory disease.

Supported through funding from Allos Therapeutics, Inc.

Historical Perspectives of T-cell Lymphoma and Etiology Overview

James O. Armitage, MD

T-cell lymphomas comprise a confusing group of illnesses, due both in part to their relative rarity as well as the circuitous route it has taken to understand their pathogenesis and natural history. Thus, a historical review of our understanding of T-cell lymphomas in the context of lymphomas in general can be helpful not only to appreciate how far we have come in understanding the disease, but also to emphasize what is still unknown. In addition to the short overview provided here, the reader is referred to several reviews published recently.[1-3]

Discovery and Classification of T-cell Lymphomas

Thomas Hodgkin, MD, provided an early description of lymphoma during the 1830s.[4] He described several patients who died with massive lymphadenopathy; autopsies were performed on these patients and results reported at a Royal College meeting. Several years later, based on these proceedings, the illness described as progressive lymphadenopathy culminating in patient mortality was given the name "Hodgkin's disease." Nearly 2 centuries later, this name still remains.

Around the turn of the 20th century, the morphology of a curious large binucleated cell was simultaneously reported by an American medical student and a German pathologist. The Reed-Sternberg cell, together with the symptoms of progressive lymphadenopathy, became associated with Hodgkin lymphoma; lymphomas without the presence of the Reed-Sternberg cell were described as non-Hodgkin lymphoma (NHL).[5] The ensuing decades saw a variety of terms introduced to further identify the NHLs. During the 1950s, Henry Rappaport, MD, published a report in which he described a classification system using cell shape together with pattern of growth[6,7]; this system became the first reproducible and clinically relevant way to subdivide the NHLs.

Importantly, at about the same time, more information was being discovered about lymphocytes, namely identifying them as the transformed cells in lymphoma. Further, the biology of lymphocytes began to become clear, and for the first time, differences between B cells and T cells were identified. The importance of B-cell or T-cell lineage in the development of lymphoma became a greatly debated question, leading the German physician Kiel Lennert, MD, and Lukes and Collins in the United States to propose a classification system that took into account whether or not the disease arose from B cells or T cells.[8,9] Later, in the United States, the "working formulation" emerged out of a large National Cancer Institute (NCI)-funded study.[10] This system did not account for either B-cell or T-cell lineage when describing the lymphoma but became the dominant American system for several years.

In the early 1990s, a group of pathologists proposed an innovative classification system, which took into account not only morphologic characteristics of the cells involved in the lymphoma, but also the immunologic and genetic characteristics of these cells, together with the observed clinical characteristics. The Revised European-American Lymphoma (REAL) classification system was validated in a large number of cases, showing it to be far more reproducible than previously used systems.[11-13] The

Disclaimer
Funding for this Monograph has been provided through an educational grant from Allos Therapeutics, Inc. Support of this monograph does not imply the supporter's agreement with the views expressed herein. Every effort has been made to ensure that drug usage and other information are presented accurately; however, the ultimate responsibility rests with the prescribing physician. Millennium Medical Publishing, Inc., the supporter, and the participants shall not be held responsible for errors or for any consequences arising from the use of information contained herein. Readers are strongly urged to consult any relevant primary literature. No claims or endorsements are made for any drug or compound at present under clinical investigation.

©2010 Millennium Medical Publishing, Inc., 611 Broadway, Suite 310, New York, NY 10012. Printed in the USA. All rights reserved, including the right of reproduction, in whole or in part, in any form.

system was found to be clinically relevant and was thus adopted by the World Health Organization (WHO) later in the decade.[14] This solidified the opinion that lymphomas should be divided according to B-cell or T-cell lineage and marked the beginning of the recognition of the complexity and variety of T-cell lymphoma subtypes. The WHO classification was most recently updated in 2008.[15]

Until recently, the lymphoma clinical trials in the United States used a classification system that grouped B-cell and T-cell lymphomas together. Because a disproportionate number of aggressive lymphomas are B-cell lymphomas, the treatments found to work most effectively in these trials were optimized for B-cell lymphomas. Thus, T-cell lymphomas were treated as rare B-cell lymphomas.[15] These conditions are different diseases, however, and it is not surprising that the treatments used did not equally improve the outcome.[16]

One of the more interesting developments in our understanding of the etiology of T-cell lymphoma came with the discovery of its association with the human T-lymphotropic virus (HTLV)-1 virus. HTLV-1, which occurs particularly frequently in the southern Japanese islands, only leads to the development of lymphoma in a small minority (approximately 10%) of infected individuals.[17] HTLV-1-associated lymphoma has become the predominant lymphoma in this region, leading the Japanese to instigate public health measures to combat its spread. These measures are aimed at stopping the spread of the virus through its primary means of transmission: blood transfusion and breastfeeding.

Delineation of T-cell Lymphoma Subtypes

While searching for markers of the Reed-Sternberg cell, German researchers discovered the Ki-1 antigen, which would later become known as CD30.[18] Further research showed that in addition to serving as a marker of the Reed-Sternberg cell, CD30 also identified the presence of a T-cell lymphoma subtype—anaplastic large cell lymphoma (ALCL).[19]

Separately, a chromosomal translocation between chromosomes 2 and 5 was identified, which led to the subsequent discovery of the anaplastic lymphoma kinase (ALK).[20] Overexpression of the ALK protein, now established to be a critical component in the carcinogenesis of some lymphoma subtypes, helped to further classify ALCL as either ALK-positive or ALK-negative.[20]

Several decades ago, pathologists had originally classified one peculiar type of lymphadenopathy as angioimmunoblastic lymphadenopathy with dysproteinemia.[21] In this illness, patients developed lymphadenopathy that had a complex histologic pattern with arborizing blood vessels and many immune abnormalities, and which ultimately progressed and was usually fatal. This disease later became known as *angioimmunoblastic T-cell lymphoma* (AITL).[22]

Many years ago, a rare disease known as lethal midline granuloma was identified as an illness that began with lesions that developed in the nose or sinuses.[23] These lesions progressed, culminating in the patient's death. It was found that this disease could be ameliorated with radiotherapy, and that it was a lymphoma involving natural killer (NK) cells. This illness became known as *nasal NK/T-cell lymphoma*.[24]

One T-cell lymphoproliferative disorder that often goes unrecognized by many oncologists and internists involves the skin. Patients with this disease develop skin lesions that will progress and develop an ulcerated center, and then eventually spontaneously disappear. This illness, often referred to as *lymphomatoid papulosis*, is one of the CD30-positive cutaneous T-cell lymphoproliferative disorders.[25]

The International T-cell Lymphoma Project

The International T-Cell Lymphoma Project collected 1,153 cases of T-cell lymphomas worldwide from adult patients with peripheral T-cell lymphoma (PTCL) or NK/T-cell lymphoma enrolled through 22 institutions/groups.[16] All patients presented with disease between 1990 and 2002. This project had several goals, including to evaluate the ability of hematopathologists to apply the WHO classification; to evaluate the role of clinical data in the diagnosis of each T-cell lymphoma subtype; to determine the relative frequencies and geographic distribution of each subtype; to determine any clinical correlations (eg, features, treatments, outcomes) associated with each subtype; and to evaluate the percentage of transformed cells, their proliferation rate, phenotype, and Epstein-Barr virus (EBV) status.

This study not only showed that the WHO classification was highly clinically relevant, but it also provided valuable information on the incidence of the various T-cell lymphoma subtypes (Figure 1). The most common of the aggressive T-cell lymphoma subtypes was reported to be PTCL not otherwise specified (PTCL-NOS), occurring in 25.9% of cases. The next most common subtypes, in order, were AITL (18.5%), NK/T-cell lymphoma (10.4%), adult T-cell lymphoma/leukemia (ATLL; 9.6%), and ALCL (ALK-positive, 6.6%; ALK-negative, 5.5%). The frequencies of the remaining T-cell lymphoma subtypes were each less than 5%.

This study also confirmed the striking geographic variation in the occurrence of the disease subtypes. PTCL-NOS is the most frequent subtype in both North America (34.4%) and Europe (34.3%), but it occurs less often in the Far East (22.4%). In contrast, NK/T-cell lymphoma and ATLL occurred at a far greater frequency

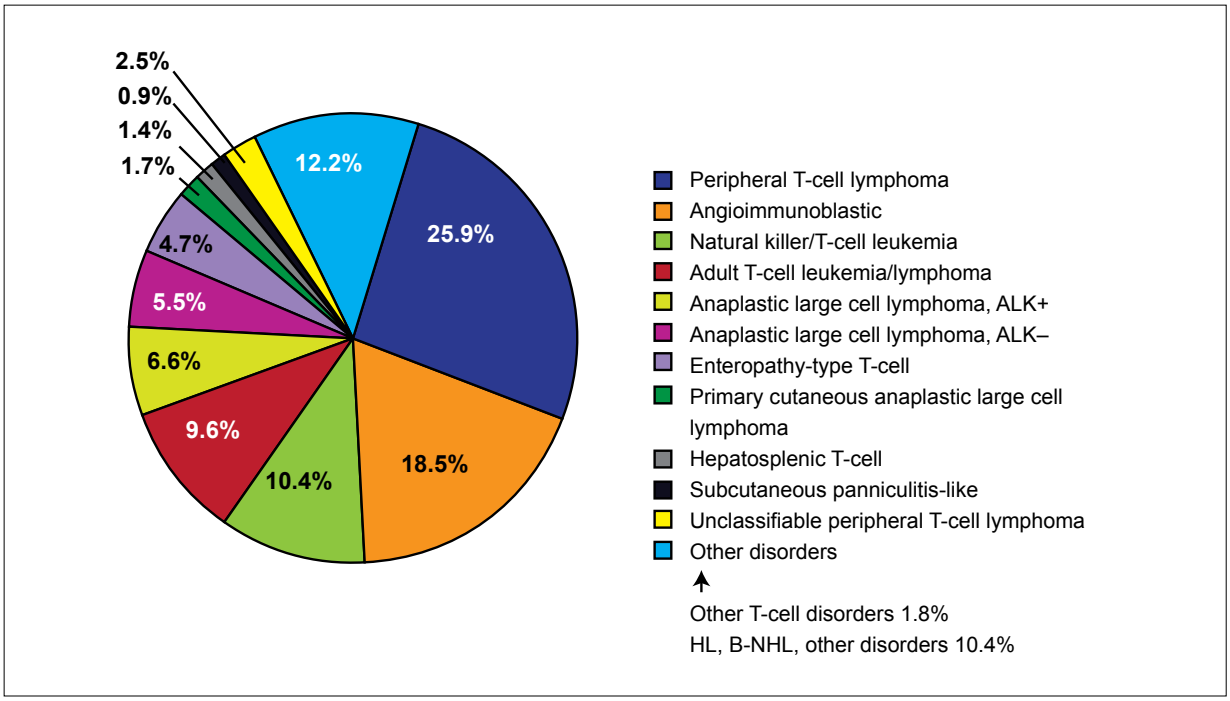

Figure 1. Lymphoma subtypes in the International Peripheral T-Cell and Natural Killer/T-Cell Lymphoma Study.

ALK=anaplastic lymphoma kinase; B-NHL=B-cell non-Hodgkin lymphoma; HL=Hodgkin lymphoma.

Adapted from Vose et al.[16]

in the Far East (22.4% and 25%, respectively) than in either North America or Europe. ALK-positive ALCL was more than twice as frequent in North America than in Europe (16.0% vs 6.4%), and AITL rates were highest in Europe (28.7%).

Another important finding in this study was that even the panel of expert hematopathologists had some difficulty diagnosing the distinct T-cell lymphoma subtypes. In the study, 2 diagnoses were made: diagnosis 1 relied upon a review of the case by 4 expert hematopathologists using histology, immunophenotype, and molecular genetic data, whereas diagnosis 2 was made after also considering clinical data. Interestingly, the addition of clinical data changed the diagnosis in 6.4% of cases among 39% of cases that were first classified as PTCL-NOS but were changed to ATLL when provided with HTLV-1 status (Table 1). The concordance between the 2 diagnoses was highest among ALK-positive ALCL (97%), ATLL (93%), and NK/T-cell lymphoma (92%). However, PTCL-NOS diagnoses were concordant in only 75% of cases, and ALK-negative ALCL in 74% of cases.

Table 1. Diagnoses in the International Peripheral T-Cell and Natural Killer/T-Cell Lymphoma Study

Subtype	Agreement of Diagnosis 2 with Consensus Diagnosis
ALCL, ALK+	97%
ATLL	93%
NK/T-cell	92%
AITL	81%
EATL	79%
PTCL-NOS	75%
Subcutaneous panniculitis-like	75%
ALCL, ALK-	74%
Hepatosplenic	72%
Primary cutaneous ALCL	66%

AITL=angioimmunoblastic T-cell lymphoma; ALCL=anaplastic large cell lymphoma; ALK=anaplastic lymphoma kinase; ATLL=adult T-cell lymphoma/leukemia; EATL=enteropathy-associated T-cell lymphoma; NK=natural killer; PTCL-NOS=peripheral T-cell lymphoma, not otherwise specified. Adapted from Vose et al.[16]

Summary

Much information about the T-cell lymphomas has become available, allowing us to finally be in a position to improve the lives of patients with these diseases. Achievement of this goal involves accurate diagnosis of the clinically and therapeutically relevant subtypes and development of therapies that are optimized for their treatment.

References

1. Armitage JO, Vose JM, Weisenburger DD. Towards understanding the peripheral T-cell lymphomas. *Ann Oncol*. 2004;15:1447-1449.
2. Macon WR. Peripheral T-cell lymphomas. *Hematol Oncol Clin North Am*. 2009;23:829-842.
3. O'Leary H, Savage KJ. The spectrum of peripheral T-cell lymphomas. *Curr Opin Hematol*. 2009;16:292-298.
4. Classics in oncology. Excerpts from: on some morbid appearances of the absorbent glands and spleen, Thomas Hodgkin. *CA Cancer J Clin*. 1973;23:54-60.
5. Schnitzer B. Hodgkin lymphoma. *Hematol Oncol Clin North Am*. 2009;23:747-768.
6. Rappaport H. Follicular lymphoma: a re-evaluation of its position in the scheme of malignant lymphoma, based on a survey of 253 cases. *Cancer*. 1956;9:792-821.
7. Rappaport H. *Tumors of the Hematopoietic System*. Washington, DC: Armed Forces Institute of Pathology. 1966;6:9-14.
8. Lennert K. Morphology and classification of malignant lymphomas and so-called reticuloses. *Acta Neuropathol Suppl*. 1975;(suppl 6):1-16.
9. Lukes RJ, Collins RD. Immunologic characterization of human malignant lymphomas. *Cancer*. 1974;34:1488-1503.
10. Berard CW, Hutchison RE. The problem of classifying lymphomas: an orderly prescription for progress. *Ann Oncol*. 1997;8(suppl 2):3-9.
11. Melnyk A, Rodriguez A, Pugh WC, Cabannillas F. Evaluation of the Revised European-American Lymphoma classification confirms the clinical relevance of immunophenotype in 560 cases of aggressive non-Hodgkin's lymphoma. *Blood*. 1997;89:4514-4520.
12. Pittaluga S, Bijnens L, Teodorovic I, et al. Clinical analysis of 670 cases in two trials of the European Organization for the Research and Treatment of Cancer Lymphoma Cooperative Group subtyped according to the Revised European-American Classification of Lymphoid Neoplasms: a comparison with the Working Formulation. *Blood*. 1996;87:4358-4367.
13. A clinical evaluation of the International Lymphoma Study Group classification of non-Hodgkin's lymphoma. The Non-Hodgkin's Lymphoma Classification Project. *Blood*. 1997;89:3909-3918.
14. Harris NL, Jaffe ES, Diebold J, Flandrin G, Muller-Hermelink HK, Vardiman J. Lymphoma classification—from controversy to consensus: the R.E.A.L. and WHO Classification of lymphoid neoplasms. *Ann Oncol*. 2000;11(suppl 1):3-10.
15. Swerdlow SH, Campo E, Harris NL, et al. *WHO Classification of Tumours of Haematopoietic and Lymphoid Tissues*. 4th ed. Lyon, France: International Agency for Research on Cancer; 2008.
16. Vose J, Armitage J, Weisenburger D. International peripheral T-cell and natural killer/T-cell lymphoma study: pathology findings and clinical outcomes. *J Clin Oncol*. 2008;26:4124-4130.
17. Yasunaga J, Matsuoka M. Human T-cell leukemia virus type I induces adult T-cell leukemia: from clinical aspects to molecular mechanisms. *Cancer Control*. 2007;14:133-140.
18. Gruss H-J, Herrmann F. CD30 ligand, a member of the TNF ligand superfamily, with growth and activation control CD30+ lymphoid and lymphoma cells. *Leuk Lymphoma*. 1996;20:397-409.
19. Oflazoglu E, Grewal IS, Gerber H. Targeting CD30/CD30L in oncology and autoimmune and inflammatory diseases. *Adv Exp Med Biol*. 2009;647:174-185.
20. Cheng M, Ott GR. Anaplastic lymphoma kinase as a therapeutic target in anaplastic large cell lymphoma, non-small cell lung cancer and neuroblastoma. *Anticancer Agents Med Chem*. 2010;10:236-249.
21. Frizzera G, Moran EM, Rappaport H. Angio-immunoblastic lymphadenopathy with dysproteinaemia. *Lancet*. 1974;1:1070-1073.
22. Yoon GS, Choi YK, Bak H, et al. Angioimmunoblastic T cell lymphomas: frequent cutaneous skin lesions and absence of human herpes viruses. *Ann Dermatol*. 2009;21:1-5.
23. Jarrett JE, Lehman RH. Lethal midline granuloma. A review of the literature. *Rocky Mt Med J*. 1971;68:40-45.
24. Kim K, Chie EK, Kim CW, Kim IH, Park CI. Treatment outcome of angiocentric T-cell and NK/T-cell lymphoma, nasal type: radiotherapy versus chemoradiotherapy. *Jpn J Clin Oncol*. 2005;35:1-5.
25. Cabanillas F, Armitage J, Pugh WC, Weisenburger D, Duvic M. Lymphomatoid papulosis: a T-cell dyscrasia with a propensity to transform into malignant lymphoma. *Ann Intern Med*. 1995;122:210-217.

Diagnosis of T-cell Lymphoma: General Principles for the Hematologist/Oncologist

Eric D. Hsi, MD

To better understand the PTCLs and their diagnoses, it is important to first be familiar with normal T-cell development.[1] Like all lymphoid cells, T cells begin their development in the bone marrow (Figure 2). Differentiation begins at the prothymocyte stage; the cells subsequently migrate to the thymus and begin to fully mature into T cells. This scripted maturation program includes progression from cortical thymocytes to common thymocytes and medullary thymocytes as they gain expression of mature T-cell markers. At this point, the cells leave the thymus and travel into peripheral areas such as the spleen, blood, lymph nodes, skin, and mucosal sites, where they become mature T cells. The majority of the mature T cells are α/β T cells, while approximately 10–15% are γ/δ T cells, distinguished by whether the cells express the α/β or γ/δ T cell antigen receptor. Within the periphery, mature T cells can undergo antigen exposure, thus differentiating from naïve T cells into memory or effector T cells. It is the mature T cells that are believed to be the normal counterparts to the transformed T cells that make up PTCLs.

Classification of Peripheral T-cell Lymphomas

The 2008 WHO classification, although complex, broadly divides NK/T-cell lymphomas into cutaneous T-cell lymphomas (CTCL) and noncutaneous PTCLs.[2] Among the

noncutaneous PTCLs, further subdivisions may be made into nodal, extranodal, and leukemic or disseminated disease. The nodal subtypes of PTCL include AITL, ALK-positive and ALK-negative types of ALCL (ALK-negative ALCL is considered a provisional entity), and PTCL-NOS. The extranodal PTCL subtypes are the nasal-type extranodal NK/T-cell lymphoma, enteropathy-associated T-cell lymphoma, and hepatosplenic T-cell lymphoma. Several types of leukemic or disseminated T-cell lymphoproliferative disorders are also identified, including T-cell prolymphocytic leukemia, T-cell large granular lymphocytic leukemia, chronic lymphoproliferative disorders of NK cells (a provisional entity), aggressive NK-cell leukemia, ATLL (HTLV1-positive), and systemic EBV-positive T-cell lymphoproliferative disorders of childhood.

When considering the WHO classification of CTCL subtypes, it is important to remember that although mycosis fungoides (MF) is the most common CTCL subtype, the term *CTCL* should not be used interchangeably with MF.[2] In addition to MF, other CTCL subtypes include Sézary syndrome (a leukemic form of MF), primary cutaneous CD30-positive lymphoproliferative disorders (lymphomatoid papulosis and primary cutaneous ALCL), and other uncommon types of CTCL. These latter types have been further subclassified based on clinicopathologic features such as subcutaneous panniculitis-like T-cell lymphoma, primary cutaneous □/□ T-cell lymphoma, primary cutaneous aggressive epidermotropic CD8-positive cytotoxic T-cell lymphoma, and primary cutaneous small/medium CD4-positive T-cell lymphoma.

Pathologic Features of Common PTCL Subtypes

PTCL-NOS

PTCL-NOS is a clinically aggressive lymphoma that typically occurs in adults ages 50–70 years. Patients usually present with high-stage disease, experiencing signs and symptoms that include generalized lymphadenopathy, B symptoms, and peripheral blood eosinophilia.[3,4]

In my opinion, the cellular morphology of PTCL-NOS cells presents several challenges to the pathologist. First, due to the rarity of this lymphoma, most pathologists will see at most 1 or 2 cases of PTCL-NOS annually; thus, it is difficult to become proficient in the diagnosis of this lymphoma subtype. Second, it has become apparent that the pathology of PTCL-NOS can be highly variable and most likely does not represent only 1 lymphoma subtype, but we do not yet have the diagnostic tools to discern the differences within this subtype. Although attempts have been made to subclassify PTCL-NOS lymphomas based on cellular size, the cytologic grading has not been shown to be of any clinical significance.[5]

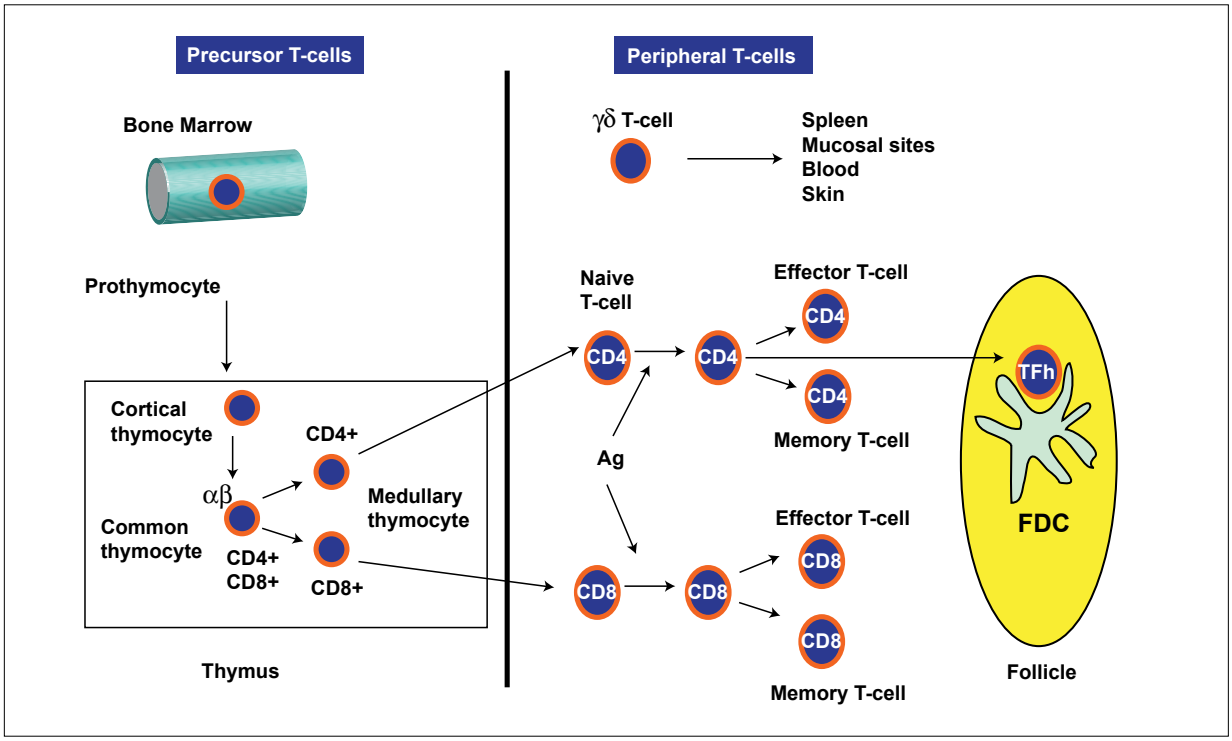

Figure 2. The development pathway of T-cells.

Ag=antigen; FDC=follicular dendritic cells; TFh=follicular helper T-cells.

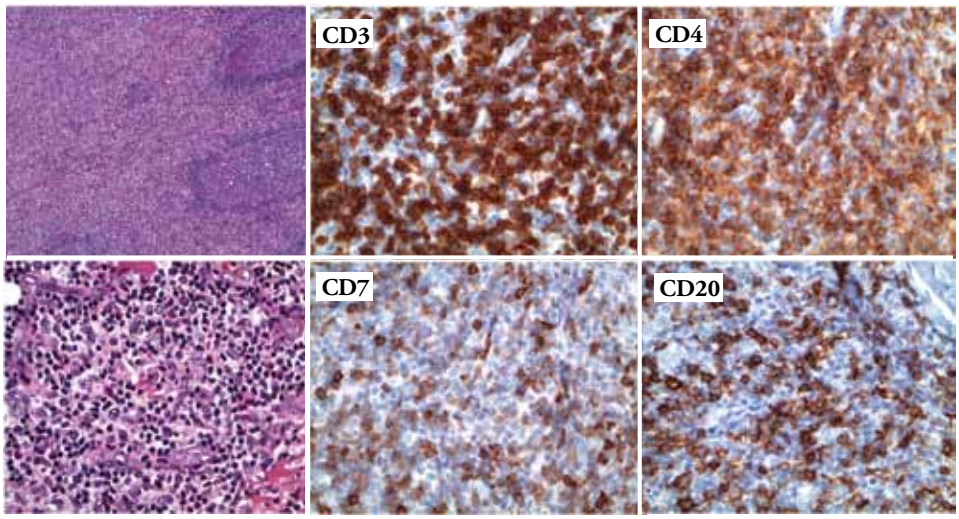

Figure 3. Peripheral T-cell lymphoma, not otherwise specified.

Generally, the morphology of PTCL-NOS is that of a paracortical or diffuse infiltrate that effaces the lymph node architecture. The lymphoma cells may have minimal or marked atypia, and they may be quite heterogeneous in appearance, even within the same tumor (Figure 3). In many cases of PTCL-NOS, the infiltrate contains a characteristic mixture of non-neoplastic inflammatory cells, including neutrophils, eosinophils, histiocytes, and other small lymphocytes.[4] It can sometimes be difficult to identify the malignant cells within the infiltrate, and therefore gene rearrangement studies are used to document the presence of a monoclonal T-cell population. These studies, together with morphologic evidence, can provide helpful clues to the diagnosis of PTCL-NOS. However, the demonstration of a monoclonal T-cell population within the infiltrate, by itself, is not sufficient evidence to support a diagnosis of PTCL-NOS. In fact, it has been well-documented that abnormal immune responses and atypical reactive hyperplasias can also exhibit this feature, thus making benign entities part of the differential diagnosis of PTCL-NOS.[6,7]

Immunophenotyping of tissue suspected of harboring a PTCL-NOS can be done in routinely fixed paraffin embedded tissues by immunohistochemistry.[5] Suitable monoclonal antibodies now exist for a broad array of pan-T-cell antigens. Immunophenotyping is an especially important step in pathologic diagnosis, because a loss of a particular T-cell antigen is considered an abnormal finding that may be observed in up to 80% of cases. This finding is unusual in inflammatory lesions and can prove helpful in the diagnosis of PTCL. However, as with gene rearrangement studies, an abnormal phenotype should not be used as the sole piece of evidence in the diagnosis of T-cell lymphoma. Most cases of PTCL-NOS are derived from CD4-positive T cells; however, other variations that occur include CD8-positive, CD4/CD8-positive, and CD4/CD8-negative.[8]

The differential diagnosis of PTCL-NOS is broad due to the heterogeneous appearance and includes reactive hyperplasias such as viral reaction and drug reactions. Also in the differential are AITL (see below), Hodgkin lymphoma, and B-cell lymphoma, such as T-cell/histiocytes rich large B-cell lymphoma.[5]

AITL

AITL, now recognized as a distinct PTCL subtype, comprises approximately 25–30% of all T-cell lymphomas.[9] This disease usually occurs in middle-aged to elderly adults, and patients often present with generalized lymphadenopathy and clinical features such as fever, weight loss, skin rashes, and arthritis. These patients often display laboratory abnormalities, including polyclonal hypergammaglobulinemia and hemolytic anemia. These tumors display a characteristic arborizing vascular pattern. AITL is an aggressive lymphoma associated with a relatively short survival.[10]

Microscopically, AITL also appears as a diffuse infiltrate. Many cases appear hypocellular due to the presence of large clear cells and increased vascularity. Reactive germinal centers are usually absent but can be observed in some early forms. One important diagnostic clue is a characteristic proliferation of follicular dendritic cells that is not associated with follicles.[11] However, like PTCL-NOS, a mixed infiltrate consisting of non-neoplastic cells may complicate diagnosis.

The immunoprofiling of AITL has shown that these cells usually express pan-T-cell antigens such as CD3 and CD4. AITL cells also express CD10, CXCL13, and PD-1.[12] Interestingly, these markers are associated with normal follicular helper T cells. Not surprisingly, studies

have now shown that these lymphomas likely arise from follicular helper T cells.[13,14]

Further complicating the diagnosis of AITL is the possible presence of a coexisting immune dysfunction within the patient. Reactivation of EBV infection can occur and may manifest as EBV-positive B immunoblasts within the T-cell lymphoma.[9] It can evolve to a monoclonal B-cell process, and patients may also develop a large B-cell lymphoma in addition to or in the background of the existing AITL.[9] Indeed it has long been known that B-cell clones could develop in AITL; however, this process was initially thought to be part of an atypical immune phenomenon rather than overt B-cell lymphoma. This phenomenon can cause difficulties in the differential diagnosis of AITL, with the B-cell process obscuring the underlying T-cell lymphoma.[15]

Although molecular profiling studies of AITL focus on the follicular helper T-cell background of this tumor, the boundaries delineating AITL from PTCL-NOS remain unclear.[13] This overlap will likely be the topic of future studies.

Like PTCL-NOS, the differential diagnosis of AITL also includes an atypical immune reaction, hyperplasia (including both viral driven and idiopathic or nonspecific cases), and Hodgkin lymphoma, as well as B-cell lymphoma as described above.[15] PTCL-NOS can also be part of the differential diagnosis; however, many features, including the proliferation of dendritic cells and follicular helper T-cell markers, can help to distinguish the 2 subtypes.[15]

ALCL

ALCL has a characteristic biphasic age distribution, affecting both younger patients (mainly adolescents, although the disease may also occur in childhood or early adulthood) and older patients (age >60 years).[9] Recently, it has become apparent that younger patients generally have ALK-positive ALCL and older patients are more likely to have ALK-negative ALCL.[16]

Histologically, it is not a challenge to identify an ALCL case as a neoplasm, mainly because of their characteristic large anaplastic cells.[9] The hallmark cells within ALCL have a comma-shaped nucleus and a cleared perinuclear area within the cytoplasm.[17] The infiltrate may only partially involve the lymph node with a characteristic sinusoidal pattern that may mimic metastatic solid tumors; however, it may also completely efface the normal lymph node architecture.[18]

CD30 is strongly expressed in all cases.[19] Further immunophenotyping shows variable expression of pan-T-cell antigens. Loss of one or more of these antigens is often seen, and at times establishing a T-cell lineage may be difficult unless numerous markers are used.[19] Indeed, before the availability of monoclonal antibodies directed against pan-T-cell antigens, many ALCLs were considered "null phenotype" due to the lack of lineage markers.[20]

In addition to typical pan-T-cell antigens, ALCL patients are now always tested for expression of ALK. Its presence defines ALK-positive ALCL. ALK expression is clinically relevant, as ALK-positive ALCL is associated with improved survival compared with other PTCL subtypes.[21,22] In the 2008 WHO classification system,[2] ALK-negative ALCL is considered a provisional entity. Although this subtype is not associated with the same high survival rate as ALK-positive ALCL, it seems to have an improved survival rate compared with PTCL-NOS, thus making the distinction important.[23]

The prototypical translocation that results in ALK expression is the t(2;5)(p23;q25), which leads to the overexpression of an abnormal fusion of *ALK* (chromosome 2p23) and *NPM* (chromosome 5q25). The resulting fusion protein leads to abnormal activation of the ALK tyrosine kinase activity. Immunostaining shows expression of ALK in the nucleus and cytoplasm of the tumor cells. It is now also known that other genes can be involved in translocation of the *ALK* gene, leading to multiple variations of fusion protein expression.[9] Some of these can be recognized by variant ALK expression patterns by immunohistochemistry. Importantly, it appears that the same favorable prognosis is seen in cases with these variant fusion partners.

T-cell Lymphoma Pathologic Work-up: General Principles

The appropriate workup of a patient with T-cell lymphoma begins with a complete history and physical, accompanied by appropriate laboratory testing and diagnostic imaging ordered by the clinician (Figure 4). Together, this information is used to decide if a biopsy is needed, and if so, what kind of biopsy will be performed. Excisional biopsies should be performed whenever clinically feasible, as this approach yields the largest amount of tissue for morphologic assessment (which includes architectural features that can be assessed only with this type of biopsy) as well as for conduct of the ancillary studies that may be needed for accurate diagnosis. Fine needle aspirate sampling should be avoided as the modality for primary diagnosis, as architectural features are lost and insufficient tissue is procured for ancillary tests. However, not all patients are appropriate candidates for excisional biopsy due to location and/or comorbidities. In such cases, needle core biopsy sample using 16- or 18-gauge needles may be performed, although it may not allow a definite diagnosis. Multiple passes are suggested to maximize yield of the procedure.

To allow maximum flexibility in the downstream diagnostic workup, tissue being tested for lymphoma

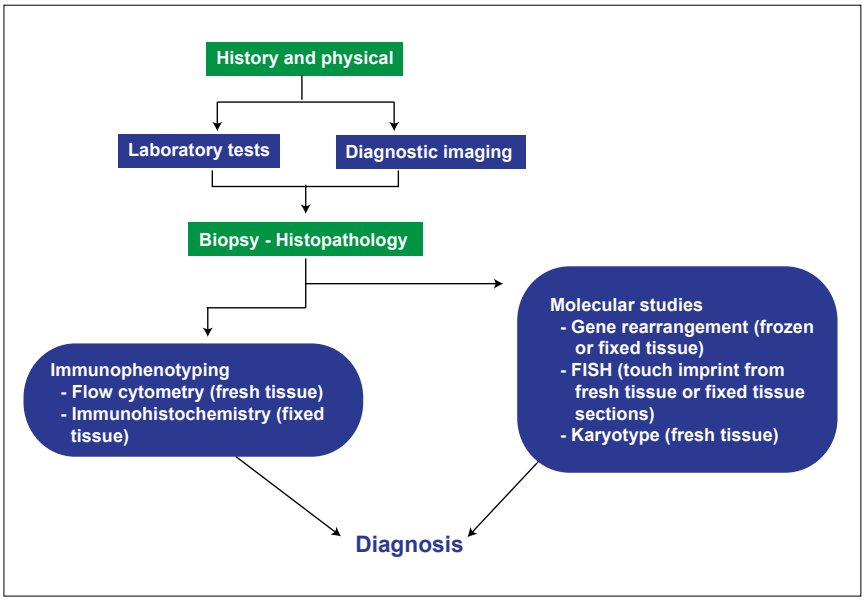

Figure 4. Diagnostic workup of a patient with T-cell lymphoma.

FISH=fluorescence in situ hybridization.

should be handled immediately in the fresh state by the pathologist so that it can be appropriately divided for ancillary studies for use as: 1) fresh tissue for flow cytometry and routine karyotyping; 2) frozen tissue for high-quality, high-molecular-weight nucleic acid isolation; and 3) routinely fixed tissue for histopathology. Together, these tissue samples allow the pathologist to perform phenotyping and potentially enable molecular studies to assist in the diagnosis and subclassification. Recently published guidelines in Britain include recommendations on the handling of tissue biopsy samples that follow the above principles.[24] When only limited tissue is available, routine fixed tissue takes precedence because paraffin section phenotyping and molecular tests can be performed in paraffin-embedded tissue, although drawbacks exist when fresh tissue is not available.

At the Cleveland Clinic, our lymphoma pathologic diagnostic protocols include many of these recommendations. The established process begins with a dialog between the clinician, the surgeon, the interventional radiologist (when appropriate), and the pathologist; all agree to send fresh samples for immediate intraoperative pathologic review by frozen section. The frozen section allows immediate assessment for adequacy. Thus, if nondiagnostic tissue is present, additional tissue can be requested. The pathologist on service then immediately processes the fresh samples, dividing them for the appropriate tests. This procedure can be adopted by smaller laboratories because appropriately handled tissue can be immediately sent to an external reference laboratory. The important step is to receive fresh tissue in the pathology laboratory so that it can undergo immediate assessment by the onsite pathologist and appropriately handled tissue can be procured prior to fixation.

Guidelines from the National Comprehensive Cancer Network for diagnosis of NHL recommend that a hematopathologist review all slides and that representative tissue blocks be available for any required phenotyping or molecular genetic studies.[25] Fine needle aspiration or core biopsy alone are not recommended because, as noted above, these often do not provide an adequate representation of the architecture of the lymph node and often can result in very limited material for ancillary studies. Provided adequate tissue is available, diagnosis and accurate subclassification of T-cell lymphoma can usually be established with a combination of careful histopathology review, immunophenotyping, and molecular tests (if needed). The number of immunophenotypic markers and tests used will vary and is dictated by the differential diagnosis.

References

1. Janeway CA, Travers P, Walport M, Shlomchik MJ. Immunobiology. 5th ed. *The Immune System in Health and Disease*. New York: Garland Science; 2001.
2. Swerdlow SH, Campo E, Harris NL, et al. *WHO Classification of Tumours of Haematopoietic and Lymphoid Tissues*. 4th ed. Lyon, France: International Agency for Research on Cancer; 2008.
3. Vose J, Armitage J, Weisenburger D. International peripheral T-cell and natural killer/T-cell lymphoma study: pathology findings and clinical outcomes. *J Clin Oncol*. 2008;26:4124-4130.
4. Pileri SA, Ralfkiaer E, Weisenburger DD, et al. Peripheral T-cell lymphoma, not otherwise specified. In: Swerdlow SH, Campo E, Harris NL, et al, eds. *WHO Classification of Tumors of the Heamatopoietic and Lymphoid Tissues*. 4th ed. Lyon, France: International Agency for Research on Cancer; 2008:306-308.
5. Rüdiger T, Weisenburger DD, Anderson JR, et al; Non-Hodgkin's Lymphoma Classification Project. Peripheral T-cell lymphoma (excluding anaplastic large-cell lymphoma): results from the Non-Hodgkin's Lymphoma Classification Project. *Ann Oncol*. 2002;13:140-149.
6. Warnke RA, Jones D, Hsi ED. Morphologic and immunophenotypic variants of nodal T-cell lymphomas and T-cell lymphoma mimics. *Am J Clin Pathol*. 2007;127:511-527.

7. Goeldel AL, Cornillet-Lefebvre P, Durlach A et al. T-cell receptor gamma gene rearrangement in cutaneous T-cell lymphoma: comparative study of polymerase chain reaction with denaturing gradient gel electrophoresis and GeneScan analysis. *Br J Dermatol*. 2010;162:822-829.
8. Savage KJ. Prognosis and primary therapy in peripheral T-cell lymphomas. *Hematology Am Soc Hematol Educ Program*. 2008:280-288.
9. de Leval L, Gaulard P. Pathobiology and molecular profiling of peripheral T-cell lymphomas. *Hematology Am Soc Hematol Educ Program*. 2008:272-279.
10. Gisselbrecht C, Gaulard P, Lepage E, et al. Prognostic significance of T-cell phenotype in aggressive non-Hodgkin's lymphomas. Groupe d'Etudes des Lymphomes de l'Adulte (GELA). *Blood*. 1998;92:76-82.
11. Dogan A, Gaulard P, Jaffe ES, et al. Angioimmunoblastic T-cell lymphoma. In: Swerdlow SH, Campo E, Harris NL, et al, eds. *WHO Classification of Tumors of the Haematopoietic and Lymphoid Tissues*. 4th ed. Lyon, France: International Agency for Research on Cancer; 2008:309-311.
12. Yu H, Shahsafaei A, Dorfman DM. Germinal-center T-helper-cell markers PD-1 and CXCL13 are both expressed by neoplastic cells in angioimmunoblastic T-cell lymphoma. *Am J Clin Pathol*. 2009;131:33-41.
13. de Leval L, Rickman DS, Thielen C, et al. The gene expression profile of nodal peripheral T-cell lymphoma demonstrates a molecular link between angioimmunoblastic T-cell lymphoma (AITL) and follicular helper T (TFH) cells. *Blood*. 2007;109:4952-4963.
14. Dupuis J, Boye K, Martin N, et al. Expression of CXCL13 by neoplastic cells in angioimmunoblastic T-cell lymphoma (AITL): a new diagnostic marker providing evidence that AITL derives from follicular helper T cells. *Am J Surg Pathol*. 2006;30:490-494.
15. de Leval L, Gisselbrecht C, Gaulard P. Advances in the understanding and management of angioimmunoblastic T-cell lymphoma. *Br J Haematol*. 2010;148:673-689.
16. Savage KJ. Peripheral T-cell lymphomas. *Blood Rev*. 2007;21:201-216.
17. Delsol G, Mason D. 'Hallmark' cells in nodal cytotoxic lymphomas. *Am J Surg Pathol*. 2000;24:1309-1310.
18. Stein H, Mason DY, Gerdes J, et al. The expression of the Hodgkin's disease associated antigen Ki-1 in reactive and neoplastic lymphoid tissue: evidence that Reed-Sternberg cells and histiocytic malignancies are derived from activated lymphoid cells. *Blood*. 1985;66:848-858.
19. Campo E, Chott A, Kinney MC, et al. Update on extranodal lymphomas. Conclusions of the Workshop held by the EAHP and the SH in Thessaloniki, Greece. *Histopathology*. 2006;48:481-504.
20. Weisenburger DD, Anderson JR, Diebold J, et al. Systemic anaplastic large-cell lymphoma: results from the non-Hodgkin's lymphoma classification project. *Am J Hematol*. 2001;67:172-178.
21. Falini B, Pileri S, Zinzani PL, et al. ALK+ lymphoma: clinico-pathological findings and outcome. *Blood*. 1999;93:2697-2706.
22. Gascoyne RD, Aoun P, Wu D, et al. Prognostic significance of anaplastic lymphoma kinase (ALK) protein expression in adults with anaplastic large cell lymphoma. *Blood*. 1999;93:3913-3921.
23. Savage KJ, Harris NL, Vose JM, et al. ALK- anaplastic large-cell lymphoma is clinically and immunophenotypically different from both ALK+ ALCL and peripheral T-cell lymphoma, not otherwise specified: report from the International Peripheral T-Cell Lymphoma Project. *Blood*. 2008;111:5496-5504.
24. Parker A, Bain B, Devereux S, et al. Best practice in lymphoma diagnosis and reporting. http://www.bcshguidelines.com/pdf/best_practice_lymphoma_diagnosis.pdf. Accessed August 30, 2010.
25. National Comprehensive Cancer Network. Non-Hodgkin's lymphoma. Clinical Practice Guidelines in Oncology 2010. http://www.nccn.org/professionals/physician_gls/f_guidelines.asp. Accessed August 20, 2010.

Prognosis of T-cell Lymphoma

Francine M. Foss, MD

PTCL Patient Outcomes

Traditionally, the outcome of patients with PTCL has been considered to be similar to patients with aggressive B-cell lymphomas. However, retrospective studies now show that the outcome of PTCL patients is actually inferior. For example, a meta-analysis of 31 studies (n=2,912) demonstrated that the 5-year overall survival (OS) of cyclophosphamide, doxorubicin, vincristine, and prednisone (CHOP)-treated PTCL patients (excluding ALCL patients because of their favorable prognosis) was 37.3% (95% confidence interval, 35.1–39.6%).[1] Furthermore, the rate of OS dramatically differed according to the PTCL histologic subtype. In one study, the 5-year OS rates in patients with nasal-type NK/T-cell, AITL, PTCL-NOS, and enteropathy-like subtypes were 47.9%, 36.5%, 34%, and 21%, respectively. In another study, the International T-cell Lymphoma Project performed an extensive evaluation of 1,153 T-cell lymphoma cases from 22 countries worldwide.[2] Importantly, when outcomes of patients who had received an anthracycline-containing regimen were compared against those who had not received anthracycline, there were no significant differences in survival. Indeed, patient outcomes were poor, regardless of treatment across all T-cell lymphoma subtypes, with the exception of ALK-positive ALCL. Although ALK-positive ALCL had the best outcome with a 5-year OS of 70%, the prognosis of ALK-negative ALCL was found to be dramatically lower and similar to that of PTCL-NOS (5-year OS was 49%). Patients with nasal-type NK/T-cell and adult T-cell leukemia subtypes have an even worse prognosis, with 5-year OS rates of 32% and 14%, respectively.

Prognostic Indices

Two different prognostic scales have been used in the diagnosis and assessment of patients with PTCL: the International Prognostic Index (IPI) and a newer scale reported in 2004 and referred to as the Prognostic Index for PTCL (PIT; Table 2).

The IPI, first developed using a patient cohort (n=2,031) of all ages, uses clinical and laboratory parameters to provide a prognostic score.[3] During the

development of the IPI, 5 factors were identified to be independently prognostic of OS: older age (>60 years), elevated lactate dehydrogenase levels (LDH) levels (>1× normal), higher Eastern Cooperative Oncology Group (ECOG) performance status (2–4), later stage (III or IV), and extranodal involvement (>1 site). The numbers of these factors are combined to determine a patient's IPI prognostic score: low (0–1 factors), low intermediate (2 factors), high intermediate (3 factors), or high (4–5 factors). The associated 5-year OS rates for each IPI score were 73%, 51%, 43%, and 26%, respectively.

PIT was later designed specifically for patients with PTCL using a retrospective cohort of 385 patients.[4] This scale is a revised version of the IPI. A multivariate analysis identified 4 factors as being significantly associated with a poor prognosis: age (>60 years; $P<.0001$), ECOG performance status (≥2; $P<.0001$), elevated LDH level (any elevation; $P<.0001$), and bone marrow involvement (any degree; $P=.026$). Using these factors, 4 risk groups were defined in the PIT: group 1 (0 factors), group 2 (1 factor), group 3 (2 factors), and group 4 (3 or 4 factors). These groups were shown to be effective prognostic categories, with corresponding 5-year OS rates (group 1: 62.3%; group 2: 52.9%; group 3: 32.9%; group 4: 18.3%) and 10-year OS rates (group 1: 54.9%; group 2: 38.8%; group 3: 18.0%; group 4: 12.6%; Figure 5).

Many clinical and laboratory findings have been evaluated for their prognostic value; several have been shown to be important in particular PTCL subtypes. Among these, ALK expression in the ALCL subtype is particularly significant; patients with ALK-positive ALCL experience a significantly prolonged OS compared to those with ALK-negative disease.[5] Both low serum albumin levels and mediastinal lymphadenopathy were independently associated with a poor OS in PTCL-NOS patients.[6] Additionally, for patients with the PTCL-NOS subtype, CD30 expression, as well as the expression markers of proliferation such as Ki-67, have been analyzed for their prognostic ability. Two chemokine receptors, CXCR3 and CCR4, were found to be expressed in 63% and 34% of PTCL-NOS cancers, respectively.[7] The dominant chemokine expression found in this study was CXCR3-positive/CCR4-negative; this phenotype was shown by multivariate analysis to be an independent prognostic factor, and to be significantly predictive of a poor prognosis in both PTCL-NOS and ALK-negative ALCL.

Recently, Went and colleagues proposed a new prognostic index based on the expression of 19 markers.[8] In retrospective studies, this score was significantly associated with patient outcome ($P<.0001$) and was more robust than the PIT score ($P=.0043$). A number of studies are under way evaluating the potential implications of chromosomal aberrations and other genetic markers.

Therapeutic Management of PTCL

Currently, there is no standard therapy for the treatment of PTCL. Because of the aggressive nature of PTCL, its treatment has historically been similar to that of aggressive B-cell lymphomas. However, retrospective reviews

Table 2. Prognostic Indices for Peripheral T-cell Lymphoma

• The PIT was developed to better define prognosis as compared with the IPI

Risk Factor	IPI	Age-adjusted IPI (age ≤60 years)	PIT
Age >60 years	•		•
Serum LDH >1× normal	•	•	•
Stage III or IV	•	•	•
Extranodal involvement >1 site	•	•	
Bone marrow involvement			•
Number of Risk Factors*	**IPI**	**Age-adjusted IPI (age ≤60 years)**	**PIT**
0	Low	Low	Group 1
1		Low intermediate	Group 2
2	Low intermediate	High intermediate	Group 3
3	High intermediate	High	Group 4
4	High	N/A	
5			N/A

*Each risk factor has a relative value of 1. IPI=International Prognostic Index; LDH=lactate dehydrogenase; PIT=Prognostic Index for PTCL.
Data for IPI from the International Non-Hodgkin's Lymphoma Prognostic Factors Project.[3]
Data for PIT from Gallamini et al.[4]

Parameter	*P* Value	Relative Risk
Age	<.0001	1.732
PS	<.0001	1.719
LDH level	<.001	1.905
BM attainment	.026	1.454
	Percentage of the Total Population (N=322)	
Group 1–0	20	
Group 2–1	34	
Group 3–2	26	
Group 4–3	20	

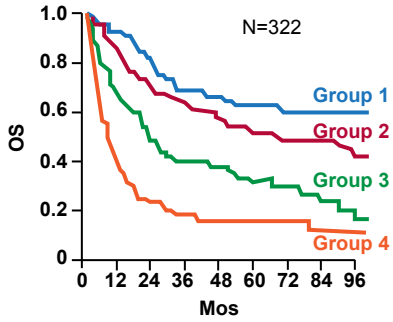

Figure 5. Overall survival according to the Prognostic Index for PTCL (PIT).

BM=bone marrow; LDH=lactate dehydrogenase; Mos=months; OS=overall survival; PS=performance status; PTCL=peripheral T-cell lymphoma.

Data from Gallamini et al.[4]

and meta-analyses show that CHOP or other conventional anthracycline-containing regimens, often used in the first-line treatment of PTCL, do not significantly improve patient outcomes.[1,2]

As an alternative, more intensive chemotherapy regimens have also been investigated in PTCL. In a large, prospective German study (n=54), over one-third (39%) of treatment-naïve patients treated with a high-dose CHOP regimen did not reach remission and were therefore ineligible for subsequent transplantation.[9] Aggressive infusional regimens, including hyper-CVAD and hyper-CHOP, among others, were evaluated retrospectively in PTCL patients (n=135) at M.D. Anderson Cancer Center.[10] Among those patients with non-ALCL disease, there was no significant difference in outcome between those treated with CHOP and aggressive alternatives (3-year OS: 43% vs 49%). However, these results are difficult to interpret, as the study was not randomized, and patients who received the aggressive regimens tended to have more aggressive disease and poorer prognosis.

A number of studies have investigated the combination of CHOP with novel agents. One of these, alemtuzumab, is a CD52-targeted monoclonal antibody. Many PTCL cases have been shown to express CD52, although expression may vary by subtype.[11] One phase II study (n=20) evaluated CHOP combined with intravenous alemtuzumab in 3-week cycles (cycle 1: 10 mg on day 1, 20 mg on day 2; subsequent cycles: 30 mg on day 1) as frontline therapy.[12] Although the overall response rate (80%) to this combination was high (65% complete response rate), nearly all patients (90%) experienced grade 4 neutropenia, and approximately one-third (32%) experienced cytomegalovirus (CMV)-related complications. Additionally, there were 2 treatment-related deaths. Because of the apparent high toxicity associated with this regimen, this study was prematurely closed. A prospective multicenter trial also investigated the CHOP plus alemtuzumab combination (n=24); in this study, alemtuzumab (30 mg) was administered subcutaneously,[13] which may result in an improved toxicity profile.[14] The complete response rate was 71%, and at a median follow-up of 16 months, 54% of patients were disease-free. The median duration of response was 11 months. Again, grade 4 neutropenia and infectious complications were the most frequent adverse events in this study, although the authors determined that these were manageable.

A phase I study evaluated alemtuzumab combined with dose-adjusted etoposide, prednisone, vincristine, cyclophosphamide, and doxorubicin (EPOCH) in PTCL patients.[15] In this study, alemtuzumab was administered at doses of 30, 60, or 90 mg prior to each EPOCH cycle. Significant bone marrow aplasia occurred in 2 of 3 patients at both the 60 and 90 mg doses; therefore, phase II study accrual is continuing at the 30 mg dose of alemtuzumab. Infections—caused by bacterial, fungal, and viral pathogens—were reported in 11 of 14 patients. Patients underwent ongoing CMV surveillance and received prophylactic therapy.

Another agent, the interleukin-2 fusion toxin protein denileukin diftitox, has also been combined with CHOP in PTCL. Recently, a phase II multicenter trial evaluated this combination for frontline therapy of patients (n=49) with aggressive lymphomas.[16] The majority of these patients had nodal PTCL subtypes (23 PTCL-NOS, 10 AITL, 6 ALCL). In this study, a 21-day cycle was used: denileukin diftitox was administered at a dose of

18 µg/kg/day on days 1 and 2, and CHOP was given on day 3; this regimen was followed by growth factor support on day 4. The overall response (90%) and complete response (76%) rates were high, and the median progression-free survival (PFS) was 15 months. Toxicities were generally associated with denileukin diftitox infusion reactions. There was no increase in infectious complications or prolonged immunosuppression.

Gemcitabine has been investigated in the treatment of PTCL because of its high activity as a single agent in T-cell lymphomas. The GEM-P combination (gemcitabine, cisplatin, methylprednisolone) was tested in 1 phase II study, producing a 69% response rate among patients with aggressive T-cell lymphomas (n=16).[17] In a pilot study, the combination of gemcitabine with vinorelbine and filgrastim was also found to be active, with an overall response rate of 70% in PTCL patients (n=10).[18] However, when gemcitabine was combined with a CHOP-based regimen (CHOP plus etoposide and gemcitabine [CHOP-EG]), the overall response rate was 77%, but the median event-free survival was a disappointing 7 months.[19]

Despite advancements in frontline therapy of PTCL, most patients have a poor prognosis, eventually going on to relapse. Thus, one strategy has been to consolidate first-line remission with stem cell transplant.[20] This strategy has been evaluated in both retrospective and prospective studies.[21] In the setting of retrospective studies among patients with PTCL of all subtypes, the 5-year OS rate was 68–70%, and the 5-year disease-free survival rate ranged from 56–63%.[21] In the prospective German study of upfront transplant, at a median follow-up of 33 months, the estimated 3-year OS and PFS rates for patients undergoing transplant were 48% and 36%, respectively.[22,23] Patients who did not experience a response to chemotherapy and therefore did not undergo autologous stem cell transplantation (ASCT) had a very poor outcome, with a median survival of less than 2 years.[22,23]

Together, these data and results from other studies demonstrate that patients with PTCL, ALCL, and AITL subtypes who experience a response to frontline chemotherapy may benefit from ASCT. However, inferior outcomes have been observed with the less common subtypes, such as disseminated NK/T-cell lymphomas, gamma delta panniculitic T-cell lymphomas, and hepatosplenic T-cell lymphomas.[21] In my opinion, these patients should be considered candidates for allogeneic stem cell transplantation if they have an appropriate donor.

References

1. Abouyabis AN, Shenoy PJ, Flowers C, et al. Response and survival rates in patients with peripheral T-cell lymphoma treated with anthracycline-based regimens: a comprehensive meta-analysis. *Blood*. 2007;110:1011a.

2. Vose J, Armitage J, Weisenburger D. International peripheral T-cell and natural killer/T-cell lymphoma study: pathology findings and clinical outcomes. *J Clin Oncol*. 2008;26:4124-4130.

3. A predictive model for aggressive non-Hodgkin's lymphoma. The International Non-Hodgkin's Lymphoma Prognostic Factors Project. *N Engl J Med*. 1993;329:987-994.

4. Gallamini A, Stelitano C, Calvi R, et al. Peripheral T-cell lymphoma unspecified (PTCL-U): a new prognostic model from a retrospective multicentric clinical study. *Blood*. 2004;103:2474-2479.

5. Savage KJ, Harris NL, Vose JM, et al. ALK- anaplastic large-cell lymphoma is clinically and immunophenotypically different from both ALK+ ALCL and peripheral T-cell lymphoma, not otherwise specified: report from the International Peripheral T-Cell Lymphoma Project. *Blood*. 2008;111:5496-5504.

6. Chihara D, Oki Y, Ine S, et al. Analysis of prognostic factors in peripheral T-cell lymphoma: prognostic value of serum albumin and mediastinal lymphadenopathy. *Leuk Lymphoma*. 2009;50:1999-2004.

7. Asano N, Suzuki R, Ohshima K, et al. Linkage of expression of chemokine receptors (CXCR3 and CCR4) and cytotoxic molecules in peripheral T cell lymphoma, not otherwise specified and ALK-negative anaplastic large cell lymphoma. *Int J Hematol*. 2010;91:426-35.

8. Went P, Agostinelli C, Gallamini A, et al. Marker expression in peripheral T-cell lymphoma: a proposed clinical-pathologic prognostic score. *J Clin Oncol*. 2006;24:2472-2479.

9. Reimer P, Ruediger T, Schertlin T, et al. Autologous stem cell transplantation as first line therapy in peripheral T cell lymphomas. Update of a prospective multicenter study. *Blood* (ASH Annual Meeting Abstracts). 2004;104:Abstract 904.

10. Escalon MP, Liu NS, Yang Y, et al. Prognostic factors and treatment of patients with T-cell non-Hodgkin lymphoma: the M. D. Anderson Cancer Center experience. *Cancer*. 2005;103:2091-2098.

11. Jiang L, Yuan CM, Hubacheck J, et al. Variable CD52 expression in mature T cell and NK cell malignancies: implications for alemtuzumab therapy. *Br J Haematol*. 2009;145:173-179.

12. Kim JG, Sohn SK, Chae YS, et al. Alemtuzumab plus CHOP as front-line chemotherapy for patients with peripheral T-cell lymphomas: a phase II study. *Cancer Chemother Pharmacol*. 2007;60:129-134.

13. Gallamini A, Zaja F, Patti C, et al. Alemtuzumab (Campath-1H) and CHOP chemotherapy as first-line treatment of peripheral T-cell lymphoma: results of a GITIL (Gruppo Italiano Terapie Innovative nei Linfomi) prospective multicenter trial. *Blood*. 2007;110:2316-23.

14. Dearden CE, Matutes E. Alemtuzumab in T-cell lymphoproliferative disorders. *Best Pract Res Clin Haematol*. 2006;19:795-810.

15. Janik J, Dunleavy K, Pittaluga S, et al. A pilot study of Campath-1H and dose-adjusted EPOCH in CD52-expressing aggressive T-cell malignancies. *Blood* (ASH Annual Meeting Abstracts). 2005;106. Abstract 3348.

16. Foss FM, Sjak-Shie NN, Goy A, et al. Phase II study of denileukin diftitox with CHOP chemotherapy in newly-diagnosed PTCL: CONCEPT trial. *J Clin Oncol* (ASCO Annual Meeting Abstracts). 2010;28:15s. Abstract 8045.

17. Arkenau HT, Chong G, Cunningham D, et al. Gemcitabine, cisplatin and methylprednisolone for the treatment of patients with peripheral T-cell lymphoma: the Royal Marsden Hospital experience. *Haematologica*. 2007;92:271-272.

18. Spencer A, Reed K, Arthur C. Pilot study of an outpatient-based approach for advanced lymphoma using vinorelbine, gemcitabine and filgrastim. *Intern Med J*. 2007;37:760-766.

19. Kim JG, Sohn SK, Chae YS, et al. CHOP plus etoposide and gemcitabine (CHOP-EG) as front-line chemotherapy for patients with peripheral T cell lymphomas. *Cancer Chemother Pharmacol*. 2006;58:35-39.

20. d'Amore F, Jantunen E, Relander T. Hemopoietic stem cell transplantation in T-cell malignancies: who, when, and how? *Curr Hematol Malig Rep*. 2009;4:236-244.

21. Reimer P. Autologous stem cell transplantation as first-line therapy in peripheral T-cell lymphomas. *Eur J Clin Med Oncol*. 2010;2:117-124.

22. Reimer P, Schertlin T, Rüdiger T, et al. Myeloablative radiochemotherapy followed by autologous peripheral blood stem cell transplantation (APBSCT) as first-line therapy in peripheral T cell lymphomas (PTCL). First results of a prospective multicenter study. *Hematol J*. 2004;5:304-311.

23. Reimer P, Rüdiger T, Geissinger E, et al. Autologous stem cell transplantation (autoSCT) as first-line therapy in peripheral T cell ASCT in peripheral T-cell lymphomas (PTCL). Results of a prospective multicenter study. *J Clin Oncol*. 2009;27:106-113.

Slide Library





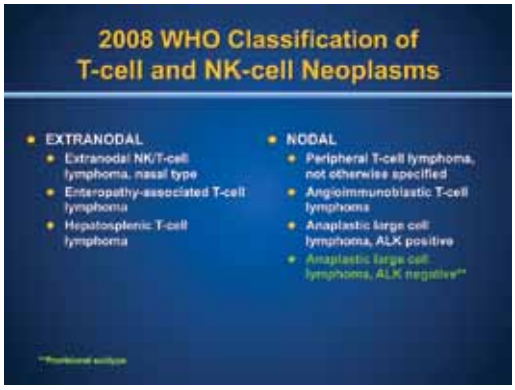

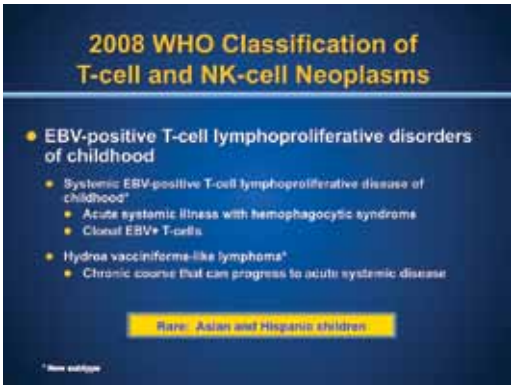





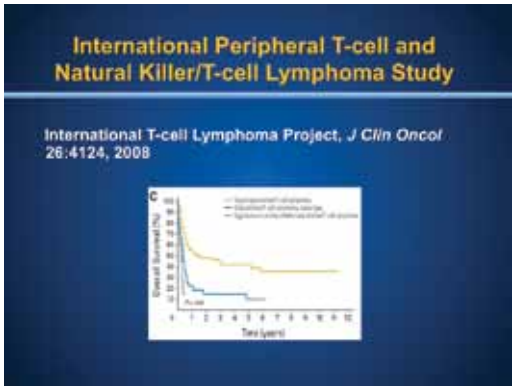

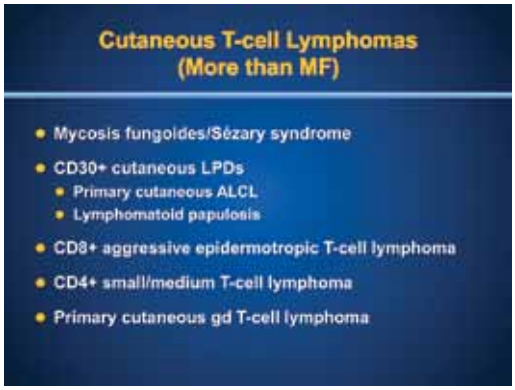

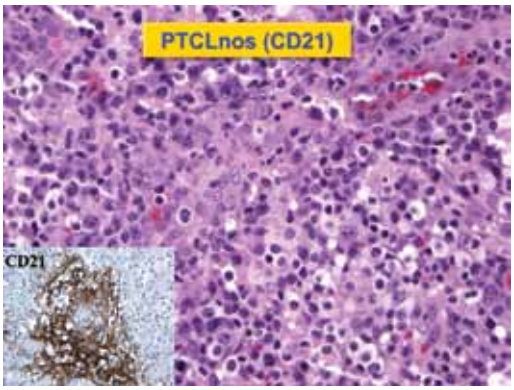

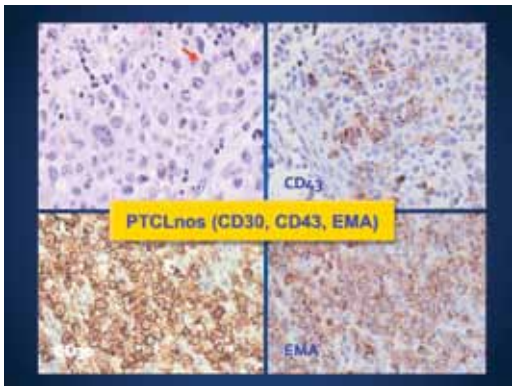

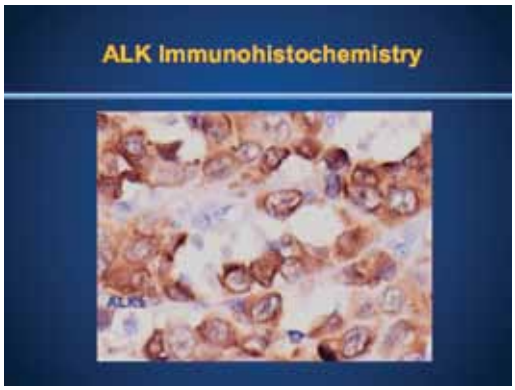

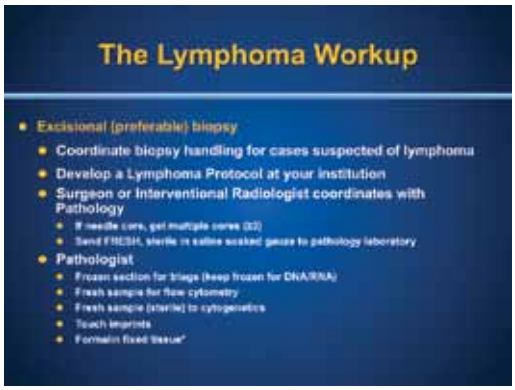

For a free electronic download of these slides, please direct your browser to the following web address:

http://www.clinicaladvances.com/index.php/our_publications/hem_onc-issue/ho_december_2010/