

Combined Factor V and Factor VIII Deficiency: A Report of a Case, Genetic Analysis, and Response to Desmopressin Acetate

John Chapin, MD¹
 Donna Cardì, RNC²
 Constance Gibb, MS²
 Jeffrey Laurence, MD¹

¹New York-Presbyterian Hospital, Weill Cornell College of Medicine, Division of Hematology-Oncology, New York, New York
²New York-Presbyterian Hospital, Weill Cornell Regional Hemophilia Center, New York, New York

Introduction

Combined factor V and factor VIII deficiency (F5F8D) is a rare, autosomal recessive congenital bleeding disorder with a prevalence of 1:1,000,000. Individuals present with a variable clinical bleeding phenotype, elevated prothrombin time (PT) and partial thromboplastin time (PTT), and plasma levels of factor V and VIII of 5–30%. Mutations in 2 proteins, LMAN1 and MCFD, required for concurrent transport of FV and FVIII through the Golgi apparatus and endoplasmic reticulum, have been identified in these patients.

Case Presentation

A 24-year-old Middle Eastern man was referred for prolonged bleeding following tooth extraction. His history was significant for prolonged bleeding after minor trauma; he had required fresh frozen plasma infusions after experiencing a tongue laceration as a child and after a lower extremity laceration as an adolescent. He had no history of hemarthroses, but had experienced gastrointestinal bleeding in the setting of peptic ulcer disease. His prothrombin time (PT) was 19 seconds, correcting to 11.5 seconds upon mixing (control, 9.8–13.2 seconds). His activated partial thromboplastin time (aPTT) was 70 seconds, correcting to 34 seconds upon mixing (control, 22.5–31.3 seconds). Platelet function assays based upon responses to collagen/epinephrine and collagen/adenosine diphosphate were within normal limits. Coagulation factor assays and a von Willebrand factor (vWF) panel were obtained. Activity levels of factors II, VII, IX, and vWF ristocetin were normal; no factor inhibitors were present. Based on a factor V activity of 5% and a factor VIII activity of 4% in the setting of a normal vWF panel, a diagnosis of F5F8D was made.

Address correspondence to:
 John Chapin, MD, New York-Presbyterian Hospital, 525 East 68th Street, New York, NY 10065; E-mail: joc9160@nyp.org.

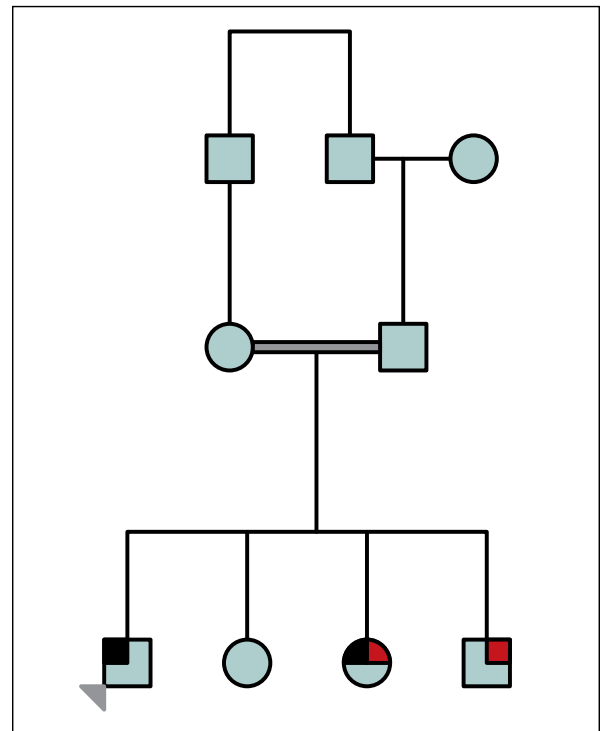


Figure 1. Pedigree of F5F8D patient. Gray arrowhead=proband; black=clinical bleeding history; red=congenital hearing loss.

Pedigree analysis revealed a sister with significant postpartum bleeding attendant upon a vaginal delivery. Both his sister and 1 brother had congenital hearing loss (Figure 1). His sister's PT, PTT, and factor V activity levels were unknown. His parents were consanguineous (first cousins; Figure 1). Genetic analysis uncovered a D81Y missense mutation in the *MCFD2* gene.

Because of his bleeding history and the unavailability of purified factor V, a desmopressin acetate (DDAVP; Sanofi-Aventis) test was performed to see if this intervention might elevate factor VIII release, and perhaps influ-

ence levels of the cotransported protein factor V. Factor V and VIII levels were measured prior to intranasal administration of 300 µg of DDAVP, and again at 30 and 60 minutes postchallenge. The vWF ristocetin cofactor activity, vWF antigen, and aPTT were also measured. Factor VIII activity increased after 30 minutes but declined to about 60% of maximal activity by 60 minutes, while factor V activity was unchanged (Figure 2). In parallel, the aPTT fell from 75.7 seconds to 70.1 seconds 60 minutes postinfusion. vWF ristocetin activity and vWF antigen levels both increased after the DDAVP infusion.

Discussion

F5F8D represents approximately 3% of all rare congenital bleeding disorders, with a prevalence of 1:1,000,000 in unselected populations.¹ Approximately 60–80% of F5F8D patients present with prolonged bleeding following injury or surgery. Gingival bleeding occurs in more than 50% of patients. Hemarthroses, typical of hemophilia A and B, occur in less than a third of patients.¹ The majority of patients are of Middle Eastern or Indian descent. The inheritance pattern is autosomal recessive. Two distinct mutations have been discovered: defects in the Lectin Mannose Binding Protein 1 (*LMAN1*), first identified in 1998; and defects in the Multiple Coagulation Factor Deficiency gene 2 (*MCFD2*), first identified in 2003.² The protein products of these genes are involved in trafficking of factors V and VIII from the endoplasmic reticulum to the Golgi apparatus. *MCFD2* and *LMAN1* normally occur in 1:1 stoichiometry and allow for the folding and transport of both coagulation factors. In the absence of one of these proteins, neither factor can be transported outside the cell and thus are not available to participate in hemostasis.

In our patient, an important diagnostic clue was his family history of consanguineous parents from the Middle East. An *LMAN1* mutation is found in approximately 70% of F5F8D patients and leads to factor V and VIII levels of 5–30%; most patients are eastern Jews.^{3,4} Of the remaining 30%, most have *MCFD2* mutations, which are more common in India and Europe. This mutation can lead to lower factor levels compared to the *LMAN1* mutations, with accompanying higher incidence of bleeding that is spontaneous or associated with minor trauma. Our patient's clinical bleeding pattern is characteristic of symptomatic F5F8D. His history of spontaneous bleeds and factor V and VIII levels corresponding to the lowest limits in previously described F5F8D cases reflects the lower factor levels that typically accompany the *MCFD2* mutation. However, other differences between patients with *LMAN1* and *MCFD2* mutations may also be involved, as distinct patterns of bleeding were recently identified in F5F8D patients

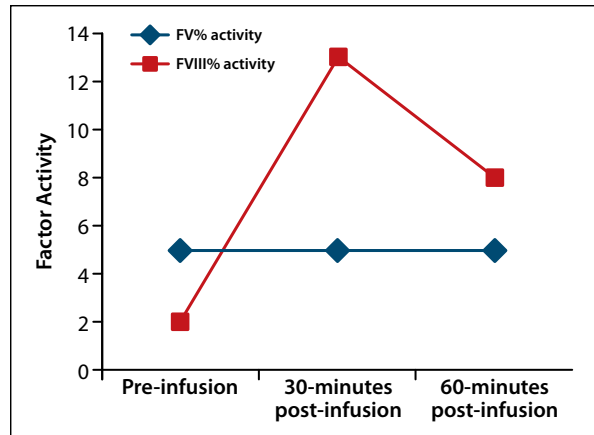


Figure 2. Factor V and factor VIII activity after intranasal administration of desmopressin acetate.

from India as compared to patients from Iran and Israel despite having similar mean factor levels.¹

The particular *MCFD2* mutation found in our patient has previously been described in 2 Saudi Arabian women.^{5,6} To our knowledge, this is the first case reported in a man. A third mutation in factor transport proteins has been hypothesized to account for F5F8D in the absence of *LMAN1* and *MCFD2* alterations, although this mutation has not been identified to date. The presence of congenital hearing loss in our patient's siblings suggests a syndromic component in the setting of parents who are first cousins, although congenital hearing loss has not previously been reported in patients with F5F8D.

Various treatment strategies have been proposed, including as-needed infusions with fresh frozen plasma, DDAVP, and recombinant factor VIII.⁷ Previous reports demonstrate a doubling of baseline factor VIII activity after DDAVP administration, as was observed in our patient.^{6,8} A more sustained and robust response to DDAVP in some cases has been documented in the setting of higher baseline levels of factor VIII.^{6,8} In our patient, enhancing the intracellular release of factor VIII by DDAVP clearly could not overcome the ER/Golgi transport deficit, similar to other reports, and factor V levels remained unchanged.^{6,8}

Summary

This case describes a very rare type of congenital bleeding disorder, F5F8D, with an identified cellular transport defect. He exhibited prolonged bleeding after minor trauma and surgery and did not mount a significant response to DDAVP in terms of factor V levels, nor did he achieve a sustained response in terms of factor VIII. Alternate methods to ensure hemostasis will be required for this patient before any planned surgical procedures.

Acknowledgment

The authors would like to thank Bin Zhang, PhD, of the Cleveland Clinic Foundation for performing the *LMAN1* and *MCFD2* genetic analyses.

References

1. Viswabandya A, Baidya S, Nair SC, et al. Clinical manifestations of combined factor V and VIII deficiency: a series of 37 cases from a single center in India. *Am J Hematol*. 2010;85:538-539.
2. Zhang B, McGee B, Yamaoka JS, et al. Combined deficiency of factor V and factor VIII is due to mutations in either *LMAN1* or *MCFD2*. *Blood*. 2006;107:1903-1907.
3. Nichols WC, Seligsohn U, Zivelin A, et al. Linkage of combined factors V and VIII deficiency to chromosome 18q by homozygosity mapping. *J Clin Invest*. 1997;99:596-601.

4. Nichols WC, Terry VH, Wheatley MA, et al. ERGIC-53 gene structure and mutation analysis in 19 combined factors V and VIII deficiency families. *Blood*. 1999;93:2261-2266.
5. Zhang B, Spreafico M, Zheng C, et al. Genotype-phenotype correlation in combined deficiency of factor V and factor VIII. *Blood*. 2008;111:5592-600.
6. Guglielmo H, Minoldo S, Jarchum G. Response to the DDAVP test in a patient with combined deficiency of factor V and factor VIII. *Haemophilia*. 2009;15:838-839.
7. Mansouritorghabeh H, Rezaieyazdi Z, Bagheri M. Successful use of factor VIII concentrate and fresh frozen plasma for four dental extractions in an individual with combined factor V and VIII deficiency. *Transfus Med Hemother*. 2009;36:138-139.
8. Garcia VV, Silva IA, Borrasca AL. Response of factor VIII/von willebrand factor to intranasal DDAVP in healthy subjects and mild haemophiliacs (with observations in patients with combined deficiency of factors V and VIII). *Thromb Haemost*. 1982;48:91-93.

Review

Combined Factor V and Factor VIII Deficiency

Gerald A. Soff, MD

Hematology Service, Department of Medicine, Memorial Sloan-Kettering Cancer Center, New York, New York

Chapin and colleagues describe an interesting case of a very rare hereditary coagulation disorder.¹ A 24-year-old man of Middle Eastern ancestry had moderate deficiencies of factors V and VIII (5% and 4%, respectively) and excessive bleeding since childhood following precipitating events. He bled excessively after tongue and leg lacerations, gastrointestinal bleeding in the setting of peptic ulcer disease, and, most recently, following tooth extraction. He was born of consanguineous parents (first cousins), and one other sibling also has had a bleeding diathesis, characteristic of an autosomal recessive trait. This case represents a classic description of a very rare bleeding disorder—combined factor V and factor VIII deficiency (F5F8D).

Chapin and colleagues also provide results of a trial of intranasal desmopressin (DDAVP; Sanofi-Aventis). DDAVP increased the factor VIII level, but not the factor V level, which was similar to the few cases previously reported. The factor VIII level increased from 2% to 13% with the single DDAVP treatment, with a clinically relevant increase persisting through 60 minutes. The factor V levels did not change after DDAVP.

There appeared to be a second, separate hereditary defect in the family: congenital hearing loss. This defect has

been described in no prior cases of F5F8D, and the clear hereditary segregation of the trait suggests it was coincidental.

Multiple Factor Deficiency Syndromes

Hereditary combined coagulation factor deficiencies are a group of very rare bleeding disorders in which a single hereditary defect results in deficiencies of more than 1 coagulation factor.^{2,3} It is unlikely that an active clinician would see more than 1 or 2 cases in an entire career, but an understanding of these diseases is of particular interest for the molecular biologic and protein biology lessons that can be learned from them.

A number of multiple factor deficiency syndromes have been described, but most are so rare that only a few families have been identified. As an example, a total of only 3 families have been reported with hereditary combined deficiencies of factors IX and XI, and little is known about this syndrome beyond its autosomal inheritance.^{3,4}

Other multiple coagulation factor deficiencies have been better characterized. Hereditary deficiency of the vitamin K–dependent factors has been described in a number of families.^{2,5} Probably the first case reported was in 1956,⁶ but at that time the diagnostic tools were quite limited. The first definitive case of hereditary deficiency of the vitamin K–dependent factors was in 1966.⁷ As the relationship of the vitamin K–dependent factors has been recognized for many years, it was no surprise that a hereditary combined deficiency syndrome would be described. As the understanding of vitamin K metabolism and the role of gamma-carboxylation of the dependent coagulation factors emerged, the specific defects causing hereditary combined deficiency of the vitamin K–dependent factors was elucidated. Recessive mutations of 2 genes, the gamma-glutamyl carboxylase gene (*GGCX*), and the vitamin K epoxide reductase gene (*VKOR*), have now been recognized.⁵

Address correspondence to:

Gerald A. Soff, MD, Hematology Service, Memorial Sloan-Kettering Cancer Center, 1275 York Ave, Howard-802, New York, NY 10065; E-mail soffg@mskcc.org.

Combined Factor V and Factor VIII Deficiency

Combined factor V and factor VIII deficiency (F5F8D) is also a very rare familial multiple coagulation factor deficiency, first reported in 1954.⁸ The estimated prevalence is 1:1,000,000, although this must be understood in the context that the majority of cases have been identified in consanguineous families, or from small gene pools in which recessive traits are much more likely to be penetrant.⁵ Most cases include Jews, Arabs, and Persians from the Middle East, as well as India.⁹⁻¹² More recently, cases have been identified more widely throughout the world.^{9,10} Within the higher risk populations, the disease has been estimated to occur as frequently as 1:100,000.¹³

Until recently, there has not been consistent nomenclature for the combined factor V and factor VIII deficiency syndrome. It has been variously referred to as familial multiple factor coagulation factor deficiency I² and multiple coagulation factor deficiency 1. The “Online Mendelian Inheritance in Man” registration is OMIM #227300 (factor V and factor VIII, combined deficiency, and abbreviated F5F8D1) and for this review, we will use the abbreviation F5F8D.

Clinical Manifestations

In F5F8D, coagulant activity and antigen levels of factors V and VIII are concomitantly low, usually between 5% and 20%.^{2,9,10} Symptoms are typical of factor deficiency disorders, and include easy bruising, epistaxis, and gingival bleeding.^{2,9,10} Postoperative bleeding is also common.^{9,10} Severe spontaneous bleeding episodes are rare, but hemarthrosis has been observed.¹⁰ The hemorrhagic manifestations are usually mild to moderate, suggesting that there is not an additive or synergistic hemorrhagic risk related to the dual deficiencies.^{2,10}

Molecular Biology

The defects causing rare bleeding disorders may teach us interesting aspects of normal coagulation and biology. For many years, the mechanism by which a single gene defect could cause the deficiency of these 2 different coagulation factors was unclear. Early on, it was recognized that the defect could not involve the genes for the 2 coagulation factors directly, since the factor V gene was autosomal whereas the factor VIII gene was X-linked.² F5FD is clearly autosomal recessive, as deduced by the fact that men and women are equally affected, the syndrome does not cross generations, and a high percentage of the cases are from consanguineous parents.^{2,9} All homozygous individuals manifest the disease, so there is complete penetrance. In 1981, Soff and Levin hypothesized that “it is interesting that these 2 factors share

a common step in their metabolism which, when abnormal, leads to the diathesis,”²² but the tools to elucidate this shared process were not yet at hand. At one point, deficiency of protein C inhibitor was proposed as the mechanism of the disease,¹⁴ however, this theory was later disproved.¹⁵

The seminal work revealing the molecular mechanism of F5FD came from Nichols and colleagues.^{16,17} Linkage of the putative gene to chromosome 18q by homozygosity mapping in 1997¹⁶ was followed by identification of specific mutations of the *ERGIC-53* gene, a component of the endoplasmic reticulum (ER)-Golgi intermediate compartment, in 1998.¹⁷ *ERGIC-53* is now known as *LMAN1* (lectin mannose binding protein).¹⁸ *LMAN1* was previously identified in the intermediate compartment between the ER and Golgi, but was of unknown function.¹⁹ Mapping F5F8D to *LMAN1* indicated that the F5F8D defect was in the post-transcriptional processing of the 2 coagulation factors, by a shared pathway.¹⁹ *LMAN1* functions as a molecular chaperone for the transport of factors V and VIII from the ER to Golgi.¹⁷

As is often the case in research, a satisfying answer subsequently appeared to be incomplete. In further studies, only approximately three fourths of cases of F5F8D syndrome had mutations of the *LMAN1* gene.¹⁹⁻²¹ This finding led to further genetic analysis in the remaining patients and identification of a second defect, referred to as *MCFD2* (multiple coagulation factor deficiency 2).²² *LMAN1* and *MCFD2* form a complex that appears to facilitate transport of specific secreted proteins, including factors V and VIII.^{19,22} The characterization of the mechanism of this rare disease has now helped to clarify this important protein-processing pathway.

The D81Y mutation present in the *MCFD2* gene identified in the current patient has been previously described by Zhang and colleagues.²³ This mutation abolishes *MCFD2* binding to *LMAN1*.²³

The large majority of known *LMAN1* mutations predict null alleles,¹⁰ yet there is always a modest basal level or both factors V and VIII. This suggests that at least some secretion of FV and FVIII may still occur in the absence of the *LMAN1:MCFD2* complex.

Treatment

Treatment of bleeding episodes or prophylaxis for surgery in patients with F5F8D has most frequently been with plasma infusion, which provides both factor V and VIII.⁹ Only modest elevations of factors V and VIII are achievable with plasma, due to volume constraints, but this is usually sufficient to control bleeding and for perioperative hemostasis.

Chapin and colleagues provide results of intranasal desmopressin (DDAVP) treatment in their patient.¹ Limited data have been previously published describing the use of DDAVP in F5F8D.²⁴⁻²⁷ In those previous cases,

as with the current case, the factor VIII coagulant activity rose at least two-fold, but the factor V levels did not increase. The patients appeared to have derived clinical benefit, despite the selective improvement of factor VIII only. This outcome suggests that the factor VIII deficiency may be more responsible for the bleeding manifestations than the factor V deficiency, or alternatively, that DDAVP provided an additional benefit that reduced bleeding, independent of simply boosting the factor VIII levels. The selective increase in factor VIII, but not factor V, in response to DDAVP indicates that it does not treat the underlying defect of the endoplasmic reticulum-Golgi intermediate compartment, specifically the *LMAN1* and *MCFD2* complex.

Conclusion

Chapin and colleagues describe a classic case of F5F8D syndrome that illustrates the key clinical and genetic characteristics of the disease. The case serves to remind us to be mindful of rare and unanticipated coagulation disorders when evaluating a patient with a bleeding history. Not all factor VIII deficiency is von Willebrand disease or hemophilia A. Patient management as well as genetic counseling necessitates a full understanding of the range of disorders.

The F5F8D disorder also illustrates the power of translational research. The systematic analysis of these rare families by Seligsohn and colleagues^{13,28} as well as others²⁹ allowed for the guided application of homozygosity mapping to identify the gene locus, and ultimately to identify the specific genes responsible for F5F8D. This allowed Chapin to send a patient sample for *LMAN1* and *MCFD2* genetic analyses.

With the elucidation of the importance of the ER-to-Golgi cargo receptor function of the *LMAN1:MCFD2* complex, research is ongoing to further understand its biologic importance. Zhang and colleagues have recently reported on *LMAN1*-deficient mice.³⁰ Mild deficiencies of factors V and VIII were observed, as would be expected, but accumulation of the ER chaperone protein GRP78 and alpha 1-antitrypsin in the liver was an unexpected finding.³⁰ Future clinical, basic science, and translational studies of F5F8D and the *LMAN1:MCFD2* complex may continue to provide valuable insight into both the bleeding disorder and other aspects of protein processing.

References

1. Chapin J, Cardi D, Gibb C, Laurence J. Combined factor V and factor VIII deficiency: a report of a case, genetic analysis, and response to desmopressin acetate. *Clin Adv Hematol Oncol*. 2012;10:472-474.
2. Soff GA, Levin J. Familial multiple coagulation factor deficiencies. I. Review of the literature: differentiation of single hereditary disorders associated with multiple factor deficiencies from coincidental concurrence of single factor deficiency states. *Semin Thromb Hemost*. 1981;7:112-148.
3. Soff GA, Levin J, Bell WR. Familial multiple coagulation factor deficiencies. II. Combined factor VIII, IX, and XI deficiency and combined factor IX and XI deficiency: two previously uncharacterized familial multiple factor deficiency syndromes. *Semin Thromb Hemost*. 1981;7:149-169.
4. Hunt CM, Carson KL, Ortel TL. Combined factor IX and XI deficiency discovered at liver biopsy. *Dig Dis Sci*. 1997;42:1731-1733.
5. Weston BW, Monahan PE. Familial deficiency of vitamin K-dependent clotting factors. *Haemophilia*. 2008;14:1209-1213.
6. Newcomb T, Matter M, Conroy L, Demarsh QB, Finch CA. Congenital hemorrhagic diathesis of the prothrombin complex. *Am J Med*. 1956;20:798-805.
7. McMillan CW, Roberts HR. Congenital combined deficiency of coagulation factors II, VII, IX and X. Report of a case. *N Engl J Med*. 1966;274:1313-1315.
8. Oeri J, Matter M, Isenschmid H, Hauser F, Koller F. [Congenital factor V deficiency (parahemophilia) with true hemophilia in two brothers]. *Bibl Paediatr*. 1954;58:575-588.
9. Spreafico M, Peyvandi F. Combined factor V and factor VIII deficiency. *Semin Thromb Hemost*. 2009;35:390-399.
10. Spreafico M, Peyvandi F. Combined FV and FVIII deficiency. *Haemophilia*. 2008;14:1201-1208.
11. Mohanty D, Ghosh K, Shetty S, Spreafico M, Garagiola I, Peyvandi F. Mutations in the *MCFD2* gene and a novel mutation in the *LMAN1* gene in Indian families with combined deficiency of factor V and VIII. *Am J Hematol*. 2005;79:262-266.
12. Viswabandya A, Baidya S, Nair SC, et al. Clinical manifestations of combined factor V and VIII deficiency: a series of 37 cases from a single center in India. *Am J Hematol*. 2010;85:538-539.
13. Seligsohn U, Zivelin A, Zwang E. Combined factor V and factor VIII deficiency among non-Ashkenazi Jews. *N Engl J Med*. 1982;307:1191-1195.
14. Marlar RA, Griffin JH. Deficiency of protein C inhibitor in combined factor V/VIII deficiency disease. *J Clin Invest*. 1980;66:1186-1189.
15. Gardiner JE, Griffin JH. Studies on human protein C inhibitor in normal and Factor V/VIII deficient plasmas. *Thromb Res*. 1984;36:197-203.
16. Nichols WC, Seligsohn U, Zivelin A, et al. Linkage of combined factors V and VIII deficiency to chromosome 18q by homozygosity mapping. *J Clin Invest*. 1997;99:596-601.
17. Nichols WC, Seligsohn U, Zivelin A, et al. Mutations in the ER-Golgi intermediate compartment protein ERGIC-53 cause combined deficiency of coagulation factors V and VIII. *Cell*. 1998;93:61-70.
18. Cunningham MA, Pipe SW, Zhang B, Hauri HP, Ginsburg D, Kaufman RJ. *LMAN1* is a molecular chaperone for the secretion of coagulation factor VIII. *J Thromb Haemost*. 2003;1:2360-2367.
19. Ginsburg D. Identifying novel genetic determinants of hemostatic balance. *J Thromb Haemost*. 2005;3:1561-1568.
20. Neerman-Arbez M, Johnson KM, Morris MA, et al. Molecular analysis of the ERGIC-53 gene in 35 families with combined factor V-factor VIII deficiency. *Blood*. 1999;93:2253-2260.
21. Nichols WC, Terry VH, Wheatley MA, et al. ERGIC-53 gene structure and mutation analysis in 19 combined factors V and VIII deficiency families. *Blood*. 1999;93:2261-2266.
22. Zhang B, Cunningham MA, Nichols WC, et al. Bleeding due to disruption of a cargo-specific ER-to-Golgi transport complex. *Nat Genet*. 2003;34:220-225.
23. Zhang B, Spreafico M, Zheng C, et al. Genotype-phenotype correlation in combined deficiency of factor V and factor VIII. *Blood*. 2008;111:5592-5600.
24. Bauduer F, Guichandut JR, Ducout L. Successful use of fresh frozen plasma and desmopressin for transurethral prostatectomy in a French Basque with combined factors V + VIII deficiency. *J Thromb Haemost*. 2004;2:675.
25. Chuansumrit A, Mahaphan W, Pintadit P, Chaichareon P, Hathirat P, Ayuthaya PI. Combined factor V and factor VIII deficiency with congenital heart disease: response to plasma and DDAVP infusion. *Southeast Asian J Trop Med Public Health*. 1994;25:217-220.
26. Devecioglu O, Eryilmaz E, Celik D, et al. Circumcision in a combined factor V and factor VIII deficiency using desmopressin (DDAVP). *Turk J Pediatr*. 2002;44:146-147.
27. Garcia VV, Silva IA, Borrascas AL. Response of factor VIII/von Willebrand factor to intranasal DDAVP in healthy subjects and mild haemophiliacs (with observations in patients with combined deficiency of factors V and VIII). *Thromb Haemost*. 1982;48:91-93.
28. Seligsohn U, Ginsburg D. Deciphering the mystery of combined factor V and factor VIII deficiency. *J Thromb Haemost*. 2006;4:927-931.
29. Ginsburg D, Nichols WC, Zivelin A, Kaufman RJ, Seligsohn U. Combined factors V and VIII deficiency—the solution. *Haemophilia*. 1998;4:677-682.
30. Zhang B, Zheng C, Zhu M, et al. Mice deficient in *LMAN1* exhibit FV and FVIII deficiencies and liver accumulation of alpha1-antitrypsin. *Blood*. 2011;118:3384-3391.