

# Granulocytic Sarcoma 12 Years Following Allogeneic Marrow Transplant for AML

Brea C. Lipe, MD  
Elizabeth Cogbill, MD  
John Hill, MD  
Kenneth Meehan, MD

*Dartmouth Hitchcock Medical Center  
Lebanon, New Hampshire*

## Introduction

Granulocytic sarcoma, a localized extramedullary tumor composed of myeloid blasts, develops in 2–6% of patients at the time of newly diagnosed acute myeloid leukemia (AML).<sup>1,2</sup> Granulocytic sarcoma relapse following an allogeneic stem-cell transplant (SCT) is associated with marrow relapse in 20% of patients.<sup>2</sup> Isolated granulocytic sarcoma following an allogeneic transplant is rare, seen in only 0.7% of patients and generally observed between 4 and 56 months after transplant, with 56 months being the longest reported duration from transplant to relapse.<sup>3</sup> Unfortunately, the majority of patients previously treated with an allogeneic SCT who relapse with an isolated granulocytic sarcoma do poorly, with a median survival of only 10 months.<sup>3</sup> Death is often related to progressive AML. Isolated granulocytic sarcoma relapse after an allogeneic SCT generally precedes marrow relapse in 95% of patients, with systemic relapse occurring within 12 months.<sup>4</sup>

## Case Report

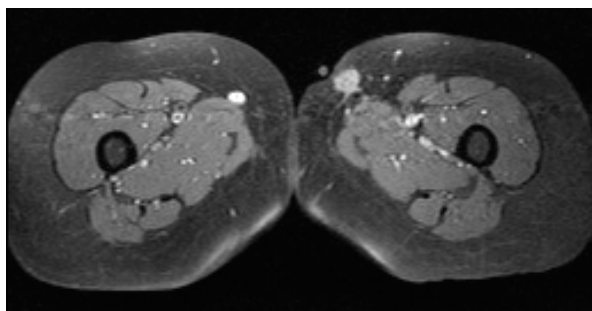
Thirteen years following treatment with phlebotomy and P32 for the treatment of polycythemia vera, a 48-year-old white woman was diagnosed with secondary AML. Cytogenetics were normal except for 1 cell with a 5q abnormality. Following a splenectomy for massive splenomegaly, the patient proceeded to a myeloablative allogeneic bone marrow transplant using her human leukocyte antigen (HLA)-matched brother's cells. Graft-versus-host-disease

(GVHD) prophylaxis consisted of methotrexate and cyclosporine. The patient developed acute GVHD of the skin (grade I/II) and liver (grade I), which responded well to steroids. Immunosuppression was tapered over 1 year, without further signs or symptoms of GVHD.

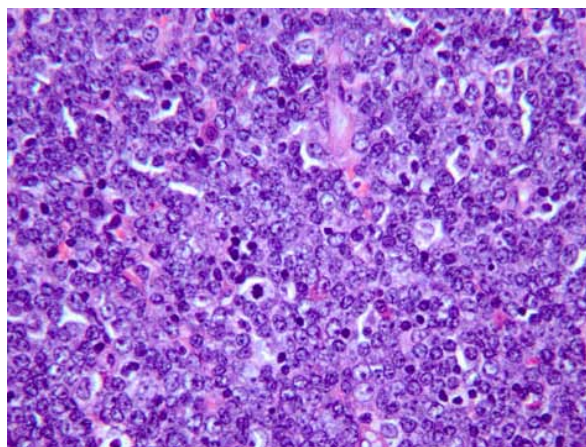
Twelve years following transplant, the patient developed an asymptomatic 3 × 2 cm subcutaneous mass in her left thigh (Figure 1). An excisional biopsy demonstrated a granulocytic sarcoma (Figure 2) with flow cytometry indicating immature myeloid cells expressing CD117, CD34, CD13, CD33, and HLA-DR. Molecular analysis of the blasts demonstrated XX chromosomes of recipient origin. A complete blood count was normal, and a bone marrow biopsy showed no evidence of AML with complete donor chimerism (XY chromosomes). Spinal fluid examination; computed tomography scans of the chest, abdomen, and pelvis; and bilateral mammograms were normal. The patient was diagnosed with an isolated granulocytic sarcoma. Following 1 course of cytarabine chemotherapy (3 g/m<sup>2</sup> twice per day on days 1, 3, and 5), a reduced intensity conditioning SCT (RIC-SCT) was performed using HLA-matched cells from the same brother. GVHD prophylaxis consisted of cyclosporine and mycophenolate mofetil. The patient engrafted well and experienced no complications. Marrow assessments on days 30, 60, and 100 following transplant demonstrated no evidence of disease, with complete donor chimerism.

Seven months after transplant and 2 months after discontinuation of immunosuppressants, the patient developed a skin rash, diarrhea, and an increase in aspartate aminotransferase (435 units/L; normal <30 units/L) and alanine transaminase (322 units/L). A skin biopsy was consistent with GVHD. Full-dose cyclosporine was initiated with pulse steroids. The serum cytomegalovirus (CMV) polymerase chain reaction was also positive. With

Address correspondence to:  
Brea Lipe, MD, University of Kansas Cancer Center, 2330 Shawnee Mission Parkway,  
Mailstop 5003, Westwood, KS 66205; Phone: 913-588-6029; Fax: 913-588-4085;  
E-mail: blipe@kumc.edu.



**Figure 1.** Magnetic resonance imaging showing left thigh mass.



**Figure 2.** Pathology slide of excised mass demonstrating granulocytic sarcoma.

the initiation of ganciclovir, the CMV titers normalized, but the rash, diarrhea, and liver function tests continued to worsen. Denileukin therapy was initiated for the skin biopsy, showing GVHD and the clinical scenario most consistent with GVHD. After 8 days of aggressive immunosuppressive therapy, a liver biopsy showed findings suspicious for veno-occlusive disease and iron overload with mild cirrhosis, but no evidence of GVHD or CMV infection. Due to persistent voluminous diarrhea, an esophagogastroduodenoscopy and a colonoscopy were performed. More than 3 weeks after starting aggressive immunosuppression, colonic and duodenal biopsies were obtained. Although the endoscopist believed the duodenum showed gross abnormalities consistent with GVHD, tissue biopsies were not pathologically consistent with acute GVHD. The patient's medical condition continued to deteriorate and she died of multiorgan failure 43 days after the onset. An autopsy request was declined.

## Discussion

While isolated granulocytic sarcoma is known to occur after allogeneic bone marrow transplant (BMT), our patient represents the longest known interval between the performance of an allogeneic transplant and isolated granulocytic sarcoma relapse. Treatment in our patient was undertaken with RIC-SCT, and despite complete donor chimerism prior to transplant, she developed progressive GVHD leading to her death. This represents a unique scenario of terminal GVHD in a patient undergoing a RIC-SCT after a prior transplant from the same donor, with intact donor chimerism at the time of RIC-SCT.

The optimal treatment for extramedullary AML presenting as granulocytic sarcoma following allogeneic transplantation is uncertain. Primary treatment involves resection, though optimal therapy remains controversial, and options range from chemotherapy with radiotherapy or a second bone marrow transplant to donor lymphocyte infusion (DLI). Although the literature is sparse on this

topic, a review of 3 cases of isolated extramedullary relapse following allogeneic BMT showed an improved median survival of 26 months in patients who maintained complete donor chimerism.<sup>5</sup> Of the 3 cases, patients appeared to respond best to local therapy with radiation, but augmentation of the graft-versus-leukemia (GVL) effect using DLI was recommended for consideration. There are scattered case reports of using azacitidine or interferon for management of isolated granulocytic sarcoma relapse, though outcomes have been disappointing.<sup>5</sup>

Evidence has shown that a second allogeneic BMT can be used for isolated granulocytic sarcoma relapse.<sup>4,5</sup> Of 4 patients, survival after second allogeneic transplant with the same donor was generally quite short, with a median survival of 17 months, but 1 patient is alive with disease more than 4 years post second BMT.<sup>4,5</sup>

Since granulocytic sarcoma after allogeneic BMT is postulated to be a failure of the GVL effect, some reports have promoted the use of DLI to augment this effect.<sup>6,7</sup> Initial results of these investigations were disappointing.<sup>8</sup> Given our patient's age of 60 years and history of an allogeneic BMT, she was considered at high risk for a second myeloablative BMT. Thus, an RIC-SCT was undertaken to augment the potential GVL effect while minimizing toxicity. In RIC-SCT, the conditioning regimen serves to suppress the host immune system, allowing for donor cell engraftment, thereby facilitating a successful graft-versus-tumor (GVT) effect.<sup>9</sup> RIC-SCT is effective in relapsed AML and presents a therapeutic option for patients at high risk for complications from a full ablative regimen in the absence of high tumor burden or rapidly progressive disease.<sup>9</sup>

While the exact etiology of granulocytic sarcoma presenting as an isolated relapse is not known, several immunologic mechanisms have been proposed. After

an allogeneic BMT, the GVL effect is likely related to immune surveillance involving T lymphocytes and natural killer cells.<sup>6</sup> Clinical evidence supporting this includes a higher relapse risk after allogeneic BMT in T-cell-depleted BMT recipients, a lower relapse risk in transplant recipients achieving full donor T-cell chimerism, and a lower risk in those who manifest active GVHD (both acute and chronic).<sup>6,10</sup>

It has been postulated that escape from immune surveillance occurs in extramedullary sites that may be protected from cytotoxic T lymphocytes.<sup>7</sup> Another hypothesis is that there are sanctuary sites for leukemic cells where the cytokine milieu required for a GVL effect and T lymphocyte functions is not able to penetrate.<sup>7</sup> For example, a common site of extramedullary relapse is the central nervous system, where the blood-brain barrier exists. The expression of CD56 on leukemic cells may contribute to homing of these cells to extramedullary sites where CD56 dimers are observed.<sup>5</sup> Likewise, CD15 has been found to be overexpressed on myeloid blasts comprising granulocytic sarcoma. This finding is intriguing since CD15 is an adhesion molecule that may allow the myeloid blasts to adhere to dermal fibroblasts and therefore facilitate migration from the bone marrow.<sup>4</sup> RIC-SCT, under these circumstances, would theoretically allow for reconstitution of the immune system and offer a therapeutic advantage.

Despite the potential for therapeutic efficacy with RIC-SCT, there are associated risks. Acute GVHD in RIC-SCT has been noted at a rate of 20–60%.<sup>11</sup> A phenomenon of late-onset acute GVHD can occur in RIC-SCT, with peak skin and gastrointestinal toxicity occurring between 6–12 months post-transplant, as opposed to the typical 3-month window seen with a myeloablative allogeneic BMT.<sup>11</sup> Our patient first developed biopsy-proven skin GVHD in association with LFT elevations 7 months following transplant, consistent with this late GVHD phenomenon. While the LFT elevations were never proven by biopsy to be related to GVHD, this may have been because the biopsies were done several weeks after initiation of aggressive immunosuppression. Our patient did have gross endoscopic evidence of GVHD, and prior studies have shown that endoscopic grading can sometimes detect GVHD when histology is negative.<sup>12</sup>

While our patient ultimately died of progressive liver failure in the setting of presumed GVHD, other factors likely played a role in her liver failure. CMV can lead to hepatocellular injury, but is also known to be reactivated by GVHD in RIC-SCT patients.<sup>13</sup> Conversely, CMV itself can act as a superantigen and lead to activation of T lymphocytes and acute GVHD. Furthermore, our patient was found to have iron overload based on ferritin level and liver biopsy. The impact of severe iron overload on

transplant patients is not fully realized, but has been linked to increased rates of GVHD, mortality, and chronic liver disease.<sup>14</sup> In the setting of systemic signs and symptoms consistent with GVHD, it seems reasonable to conclude that the combination of GVHD, CMV, and iron overload may have contributed to the progressive liver failure.

In summation, the exact underlying pathophysiology for isolated granulocytic sarcoma relapse in a patient presenting long after initial diagnosis and the subsequent progressive and refractory GVHD in the setting of full donor chimerism prior to transplant remains unknown. However, it seems plausible that both relapse and ultimate GVHD may be related to T-cell function. While the patient maintained donor chimerism in the marrow, she may have lost full T-cell chimerism, allowing for the development of the isolated granulocytic sarcoma in the periphery. Likewise, the impact of the RIC-SCT on the reconstitution of donor T-cell chimerism may have allowed for the GVHD that ultimately led to the patient's demise. This is supported by the timing of the GVHD and the occurrence of CMV around the same time, both of which are predicted with T-cell reconstitution. To our evaluation, there have been no reports of donor T-cell chimerism in isolated granulocytic sarcoma relapse. With the increasing use of BMT and the growing availability of transplants to a wider range of patients, further understanding of the immune mechanisms surrounding both GVHD and the GVT effect remains a priority.

## References

1. Neiman RS, Barcos M, Berard C, et al. Granulocytic sarcoma: a clinicopathologic study of 61 biopsied cases. *Cancer*. 1981;48:1426-1437.
2. Byrd Edenfield WJ, Shields DJ, Dawson NA. Extramedullary myeloid tumors in acute nonlymphocytic leukemia: a clinical review. *J Clin Oncol*. 1995;13:1800-1816.
3. Bekassy AN, Hermans J, Gorin NC, Gratwohl A. Granulocytic sarcoma after allogeneic bone marrow transplantation. *Bone Marrow Transplant*. 1996;17:801-808.
4. Koc Y, Miller KB, Schenkein DP, Daoust P, Sprague K, Berkman E. Extramedullary tumors of myeloid blasts in adults as a pattern of relapse following allogeneic bone marrow transplantation. *Cancer*. 1999;85:608-615.
5. Au WY, Chan AC, Lie AK, Chen FE, Liang R, Kwong YL. Recurrent isolated extramedullary relapses as granulocytic sarcomas following allogeneic bone marrow transplantation for acute myeloid leukemia. *Bone Marrow Transplant*. 1998;21:205-208.
6. Dermime S, Mavroudis D, Jiang YZ, Hensel N, Mollidrem J, Barrett AJ. Immune escape from a graft-versus-leukemia effect may play a role in the relapse of myeloid leukemias following allogeneic bone marrow transplantation. *Bone Marrow Transplant*. 1997;19:989-999.
7. Park Y, Park SY, Cho HI, Lee D. Isolated extramedullary relapse in the pleural fluid of a patient with acute myeloid leukemia following allogeneic BMT. *Bone Marrow Transplant*. 2002;30:57-59.
8. Nachbaur D, Duba HC, Feichtinger H, et al. Polychemotherapy combined with G-CSF mobilized donor buffy coat transfusion for granulocytic sarcoma after BMT for AML. *Bone Marrow Transplant*. 1997;19:947-949.
9. Sandmaier BM, Mackinnon S, Childs RW. Reduced intensity conditioning for allogeneic hematopoietic cell transplantation: current perspectives. *Biol Blood Marrow Transplant*. 2007;13:87-97.
10. Baron F, Maris MB, Sandmaier BM, et al. Graft-versus-tumor effects after allogeneic hematopoietic cell transplantation with nonmyeloablative conditioning. *J Clin Oncol*. 2005;23:1993-2003.

11. Mielcarek M, Martin PJ, Leisenring W, et al. Graft-versus-host disease after nonmyeloablative versus conventional hematopoietic stem cell transplant. *Blood*. 2003;102:756-762.
12. Cheung DY, Kim JI, Kim SS, et al. Endoscopic evaluation in gastrointestinal graft-versus-host disease: comparisons with histological findings. *Dig Dis Sci*. 2008;53:2947-2954.

13. Pinana JL, Martino R, Barba P, et al. Cytomegalovirus infection and disease after reduced intensity conditioning allogeneic stem cell transplantation: single-centre experience. *Bone Marrow Transplant*. 2010;45:534-542.
14. Sucak GT, Yegin ZA, Ozkurt ZN, Aki SZ, Karakan T, Akyol G. The role of liver biopsy in the workup of liver dysfunction late after SCT: is the role of iron overload underestimated? *Bone Marrow Transplant*. 2008;42:461-467.

## Review

### Relapsed AML Post–Allogeneic Hematopoietic Stem Cell Transplantation

Emma Nicholson, MD, and Stephen Mackinnon, MD

*Department of Haematology  
Royal Free Hospital NHS Trust  
London, United Kingdom*

#### Graft-Versus-Leukemia and Graft-Versus-Host Responses in Acute Myeloid Leukemia

Lipe and colleagues<sup>1</sup> describe a case of a patient with secondary acute myeloid leukemia (AML) treated with allogeneic hematopoietic stem cell transplantation (HSCT) who had an isolated extramedullary relapse 12 years after HSCT. Isolated extramedullary relapse is a very rare event following HSCT and is associated with a very poor prognosis. Allogeneic hematopoietic stem cell transplantation (HSCT) is an effective treatment for patients with high-risk acute myeloid leukemia (AML), but the main cause of death post-transplant remains disease relapse.<sup>2</sup> A recent meta-analysis comparing allogeneic HSCT to non-allogeneic treatments for AML has shown a significant relapse-free survival and overall survival (OS) benefit for high- and intermediate-risk AML patients treated in first complete remission with allogeneic HSCT.<sup>3</sup> The number of allogeneic HSCTs being performed for the treatment of AML is increasing with the more widespread use of reduced intensity

conditioned (RIC) HSCT, which extends this treatment to older patients or those with comorbidities. RIC regimens use immunosuppressive conditioning that promotes engraftment but relies more heavily on graft-versus-leukemia (GVL) effects for leukemia eradication. RIC regimens are associated with lower treatment-related mortality (TRM) than traditional myeloablative regimens, but this is offset by an increased relapse risk. Although there has been no randomized controlled trial comparing myeloablative and RIC HSCT for the treatment of AML, analysis suggests that OS and progression-free survival (PFS) are similar for patients that are transplanted in first complete remission.<sup>4</sup> Dose intensity of the conditioning regimen, however, may be more important for patients in second complete remission or those with refractory disease.

Achieving durable remissions following allogeneic HSCT is therefore partly reliant on the ability of transferred donor lymphocytes to direct alloreactive responses against recipient leukemia cells inducing a GVL response. In a human leukocyte antigen (HLA) mismatched setting, alloreactive donor T cells recognize recipient major histocompatibility complex (MHC) molecules. In fully HLA-matched transplants, the alloresponse is directed against minor histocompatibility antigens (mHags) presented by host antigen presenting cells (APC). mHags are polymorphic peptides that are derived from cellular proteins that differ between a donor and recipient and may be ubiquitously expressed on self-tissues or restricted to hematopoietic tissues. In addition, GVL responses are directed against leukemia-associated antigens, which are normal self-antigens that are overexpressed or aberrantly expressed by leukemia cells. In addition to alloreactive T cells, natural killer (NK) cells are key effectors in the GVL response directed against AML. NK cell function is mediated by both activating and inhibitory killer cell immunoglobulin receptors (KIR). Inhibitory KIRs recognize self-MHC molecules and, following HSCT, donor NK cells lyse targets that do not express cognate MHC molecules. KIR ligand mismatch has been shown to be important in maintaining durable remission following haploidentical transplant for AML,<sup>5</sup> where

Address correspondence to:

Emma Nicholson, MD, Department of Haematology, Cancer Institute, University College, Gower Street, London, UK, WC1E 6BT; Phone: +44 (0)20 7679 2000; Email: e.nicholson@ucl.ac.uk

KIR ligand mismatched donors were associated with improved engraftment, decreased relapse, and decreased GVHD. In unrelated HSCT, use of donors with KIR B haplotypes has been shown to be associated with an improvement in OS and PFS.<sup>6</sup>

In addition to targeting leukemia cells, alloreactive donor cells also target antigens expressed on normal tissues leading to harmful GVHD responses. Acute GVHD occurs after activation of host APCs by the conditioning regimen, resulting in presentation of alloantigens to donor T cells. These cells attack ubiquitously expressed mHags on non-hematopoietic tissues. Activated donor CD4-positive T cells generate inflammatory cytokines, resulting in non-specific tissue damage and further activation of alloreactive T cells, which leads to a self-perpetuating cycle of tissue damage and cytokine release. In T-cell-replete myeloablative HSCT, the development of GVHD is associated with a reduction of relapse risk, but this does result in a higher TRM.<sup>7,8</sup> Although the use of RIC reduces TRM, T-cell-replete RIC HSCT is still associated with high levels of acute and chronic GVHD.<sup>9,10</sup>

After allogeneic HSCT, the majority of relapses occur within the first 12 months. The ability to monitor patients post-transplant to detect early molecular relapse may allow more effective preemptive treatment than at time of full hematologic relapse and may improve long-term disease-free survival.

### Chimerism Monitoring Post-Allogeneic HSCT

Immediately following HSCT, both donor and host hematopoiesis will coexist. With time, there is gradual evolution to full donor hematopoiesis resulting in full donor chimerism. Eradication of host hematopoiesis can be achieved with more intensive conditioning regimens or can be a function of the transferred donor T cells, which eradicate both normal host hematopoiesis and leukemic cells leading to stable engraftment. The persistence or reappearance of host hematopoiesis following HSCT is termed *mixed chimerism*. This may be a result of reappearance or survival of the leukemic clone or of normal host hematopoiesis. Mixed chimerism suggests that donor T cells are tolerant to the host and vice versa, and this may lead to attenuation of GVL responses or to graft rejection. Alternatively, the persistence of host APCs may actually promote GVL effects.

In patients with chronic myeloid leukemia (CML) who received T-cell-depleted myeloablative HSCT, a finding of T-cell mixed chimerism was associated with the presence of residual disease and eventual hematologic or molecular relapse.<sup>11</sup> Administration of donor leukocyte infusion (DLI) can convert mixed to full donor chimerism and lead to disease regression.<sup>12</sup> In AML patients,

particularly following RIC or non-myeloablative HSCT, the use of chimerism to predict relapse is less clear cut. Baron and colleagues looked at the kinetics of engraftment post-HSCT conditioned with low-dose total body irradiation and fludarabine.<sup>13</sup> They found that the majority of patients retained some degree of T-cell mixed chimerism for up to 6 months post-transplant. Donor T-cell and NK-cell levels of less than 50% at day 14 post-transplant were associated with graft rejection, and a high level of donor T cells at day 29 was associated with the occurrence of grade II–IV acute GVHD. A high level of donor T-cell and NK-cell chimerism from days 14–42 was associated with a decreased risk of relapse and high levels of donor NK cell chimerism correlated with improved PFS. Achievement of full donor chimerism was associated with a lower risk of disease progression. Mohty and associates performed a retrospective analysis of patients with myeloid malignancies conditioned with fludarabine/busulphan/anti-thymocyte globulin or fludarabine/low-dose TBI and demonstrated that patients with full donor T-cell chimerism on day 30 had a higher incidence of grade II–IV GVHD, and patients with mixed chimerism on day 90 had a higher incidence of relapse.<sup>14</sup> Valcarcel and coauthors used a prospective study to evaluate the effects of early chimerism measurements in HSCT patients conditioned with fludarabine/melphalan or fludarabine/busulphan. The probability of achieving stable full donor chimerism within 6 months was 95% based on measurements on day 180 post-transplant. This study did not demonstrate any correlation between the rate of achieving full donor chimerism and incidence of acute GVHD or disease progression.<sup>15</sup>

Whilst there is some conflicting evidence, the serial measurement of chimerism post-HSCT for AML is recommended. For patients with a progressive loss of donor T-cell chimerism, intervention with DLI may convert back to full donor chimerism and stable disease remission.

### Donor Lymphocyte Infusion

DLI can be used to re-induce full donor chimerism in patients with mixed or falling donor chimerism, to treat frank hematologic relapse, or it can be given prophylactically to patients considered at high risk of relapse post-HSCT. DLI for treatment of frank hematologic relapse of AML is of limited efficacy, with long-term survival of only 10–15%.<sup>16–18</sup> The European Bone Marrow Transplantation Group performed a retrospective analysis of patients with AML in first hematologic relapse post-allogeneic HSCT. The findings showed superior estimated OS at 2 years for those patients receiving DLI for treatment of relapse compared to those who did not receive DLI (21% vs 9%).<sup>16</sup> However, if DLI was given

in the setting of persistent disease, the response rates were very low. In this study, the factors associated with an improved outcome following relapse were younger age, relapse occurring more than 5 months post-transplant, and the administration of DLI.

DLI can be combined with chemotherapy to reduce disease burden prior to administration, which may improve efficacy in relapsed AML. Choi and coworkers performed a prospective study using cytoreductive chemotherapy immediately followed by granulocyte colony-stimulating factor–primed DLI for treatment of relapse of AML post–allogeneic HSCT.<sup>19</sup> The complete remission rate was 63% and the OS rate at 2 years was 31%, with a TRM rate of 25%. The length of remission post-allograft was significantly associated with outcome: in those with remission duration of more than 6 months, the 1-year OS rate was 55%. This approach may be useful in selected patients with long duration of remission and may produce a lower TRM than a second allogeneic transplant procedure.

Preemptive DLI given prior to the detection of relapse or mixed chimerism has been studied in AML. Schmid and colleagues used a sequential conditioning regimen of cytoreductive chemotherapy followed by T-depleted RIC in 75 patients with high-risk AML.<sup>20</sup> They then gave preemptive DLI at day 120 to augment the GVL effect, once tolerance had been established. DLI was given on an escalating dose schedule to patients who had no GVHD and had weaned immunosuppressants by day 120. Two-year OS and PFS rates were 42% and 40% in this high-risk group. It is likely that if DLI is going to be effective in AML patients, it needs to be administered prior to hematologic relapse detected either by worsening mixed chimerism or minimum residual disease (MRD).

The main complication of DLI is GVHD, which is highest in patients with unrelated or mismatched donors.<sup>21</sup> Severity and incidence of GVHD post-DLI correlates with the dose of DLI given. Using escalation of the DLI dose to achieve disease control at the minimum required dose can reduce GVHD.<sup>12</sup> In addition, delaying the timing of DLI administration post-allogeneic HSCT also reduces the incidence of GVHD. Delaying the infusion of DLI allows the inflammation arising post-conditioning to abate and thus may reduce activation of host APCs. Strategies to reduce GVHD after DLI also include graft manipulation to deplete CD8-positive T cells, which are thought to be one of the main effector cells causing GVHD. In addition, due to the restricted expression of class II MHC by professional APCs, the infusion of a purified population of donor CD4-positive T cells may reduce damage to peripheral class II negative tissues. The use of CD8-positive depletion to produce purified populations of CD4 T cells for DLI has been shown to be feasible on a clinical scale.<sup>22,23</sup> CD4-positive T cells used at escalating doses can be used to con-

vert mixed chimerism to full donor chimerism in patients post-RIC. GVHD did occur following CD4-positive DLI, but a randomized controlled trial is required to directly compare its effects with unmanipulated DLI.

### Minimal Residual Disease Monitoring Post-Allogeneic HSCT for AML

MRD monitoring by real-time quantitative polymerase chain reaction (RQ-PCR) to detect leukemia-specific targets (eg, mutations or fusion gene transcripts) may be utilized to predict patients at high risk of relapse post-transplant. AML is a very genetically heterogeneous disease with multiple different gene mutations described, and therefore finding a universal target gene to use for MRD monitoring is complex.

A total of 50% of patients with AML have a normal karyotype, and the most frequent mutation within this subgroup is the nucleophosmin 1 protein (NPM1) mutation.<sup>24,25</sup> Patients with isolated NPM1 mutations have a more favorable prognosis with higher rates of complete remission and longer DFS compared to wild-type patients. After chemotherapy, monitoring of NPM1 has been used as an MRD marker. MRD-positive patients post-consolidation chemotherapy had a significantly higher relapse risk than those who were MRD negative.<sup>26</sup> After allograft, a correlation between the persistence of the NPM1 mutation and relapse has been demonstrated, with a short interval seen from an increase in NPM1 and relapse.<sup>27</sup>

Flt3 is a class III receptor tyrosine kinase expressed in early bone marrow progenitors. Duplications of the internal tandem domain are found in 40% of cytogenetically normal cases of AML. These mutations are localized to the transmembrane domain, and the insertions are of variable length and have a varying degree of genomic instability. Patients with a Flt3 internal tandem duplication (ITD) have a poor outcome following treatment with chemotherapy and should be offered allogeneic HSCT in first complete remission.<sup>28,29</sup> After allograft, the use of Flt3 as a molecular marker is not straightforward, as the mutation requires a patient-specific primer and the instability of the mutation can lead to loss of mutation in about 20% of patients after relapse.

Wilms' tumor 1 (WT1) antigen is overexpressed in 80–100% of AML patients,<sup>30,31</sup> and acquired mutations of WT1 are found in about 10% of cytogenetically normal AML. The WT1 gene encodes a transcription factor involved in cellular growth and metabolism, with functions of both a tumor suppressor gene and oncogene. Following induction chemotherapy, early reduction in WT1 levels can be detected by RQ-PCR, and this correlates with a low incidence of relapse and improved PFS and OS, suggesting that this could be a useful MRD marker.<sup>33,33</sup>

In the allogeneic HSCT setting, WT1 levels pre- and post-transplant correlate with remission status before and after allogeneic SCT. Candoni and colleagues measured WT1 levels prior to allograft and at defined time points post-RIC HSCT in 25 patients (all of whom had high levels of WT1 at diagnosis).<sup>34</sup> Of the 25 patients, 18 were in complete remission (CR) at time of allogeneic HSCT and 7 were refractory. Pretransplant WT1 levels were significantly lower in patients with CR compared to those with refractory disease. In the 18 patients transplanted in CR, 17 remained in stable CR after transplant, and in all of these patients, WT1 levels remained low. Three of the refractory patients achieved CR post-allogeneic HSCT and had a corresponding fall in WT1 levels. All patients who relapsed had a high level of WT1 prior to hematologic relapse. In 50% of these patients, an increase in WT1 levels was seen prior to loss of full donor chimerism.

Lange and associates<sup>35</sup> used a combination of CD34-positive donor chimerism in bone marrow and WT1 expression in peripheral blood to predict hematologic relapse following non-myeloablative conditioned allogeneic HSCT. Patients who relapsed had significantly higher levels of WT1 expression in the blood at day 28 post-allograft than those without impending relapse. Using a cutoff level of WT1 expression that was 10 times higher than that seen in normal peripheral blood, those with high WT1 expression at day 28 had a 79% risk of relapse. Using a combination of a more than 5% reduction of CD34-positive donor chimerism and high WT1 transcript level, 100% of patients at risk of relapse could be identified with a specificity of 84%. If there was a WT1 level below the cutoff and less than a 5% decrease in CD34 chimerism, then relapse at this point could be excluded entirely.

Alternatively, MRD can be measured using multi-parametric flow cytometry (MFC) to detect a combination of cell surface antigens that make up a leukemic-associated immunophenotype expressed by the AML cells. Walter and associates used 10-color MFC to measure MRD in bone marrow aspirates before HCT.<sup>36</sup> A total of 24 patients were MRD-positive pretransplant. The estimated 2-year OS rate was 30% for those who were MRD-positive pretransplant and 77% for those who were MRD-negative pretransplant. The 2-year estimates of relapse risk were 65% and 18% for the MRD-positive group compared to the MRD-negative group. A potential drawback of this approach is that loss of leukemic-associated immunophenotype can occur in up to 25% of patients following allograft.

## Second HSCT for Treatment of Relapsed AML

AML relapsing post-HSCT has a very poor long-term outcome when treated with chemotherapy alone. Second

allogeneic HSCT for treatment of relapsed AML is an option in selected patients. Retrospective data collected for patients who received myeloablative HSCT for treatment of relapsed hematologic malignancies showed very high TRM rates of 40–50%.<sup>37,38</sup> Long-term disease survival was possible in some patients, with improved OS and leukemia-free survival observed in patients who had relapsed more than 1 year post-transplant and in patients with a low disease burden at time of second allograft. A more recent analysis of 279 patients with acute leukemia relapsing after HLA-matched sibling allograft reported a cumulative incidence of relapse of 42% and TRM of 30% at 5 years. Both myeloablative and RIC second transplants were analyzed, and this study found a higher risk of relapse in patients who received RIC for their second transplant. The 5-year OS and LFS rates were 28%. Risk of relapse was lowest in patients who relapsed more than 6 months after initial transplant and in patients who were in CR prior to second transplant.<sup>39</sup>

Given the low TRM correlated with RIC regimens, it is likely that the TRM associated with the use of subsequent RIC as a second allograft will also be lower. An analysis of 71 patients with relapsed hematologic malignancies who received RIC prior to second allograft demonstrated a relatively low TRM of 24% at 1 year and predicted OS at 2 years of 28%.<sup>40</sup> Patients that relapsed more than 1 year post-transplant had the best outcomes, with TRM of only 13% at 1 year.

One of the main factors therefore in selecting patients for eligibility for second transplant is timing of relapse post first allograft. Benefit is likely to be restricted to patients who can achieve a CR, have a low disease burden at time of HSCT, and a longer duration from time of first allograft. Use of RIC in particular appears to reduce TRM to acceptable levels, although the majority of patients will still die of disease progression. There is no current evidence to suggest the superiority of second allogeneic HSCT over DLI for treatment of relapsed AML after HSCT; treatment should be selected on an individual patient basis.

## Conclusion

Outcomes following allogeneic HSCT for treatment of AML continue to improve, but a significant proportion of patients will still relapse post-transplant. Serial chimerism measurement and development of MRD markers for use for monitoring of AML patients post-HSCT may allow detection of molecular relapse. Further adoptive transfer of donor lymphocytes, either as DLI or a second allogeneic HSCT, is likely to be more effective in achieving prolonged remission if administered prior to full hematologic relapse.

## References

1. Lipe BC, Cogbill E, Hill J, Meehan K. Granulocytic sarcoma 12 years following allogeneic marrow transplant for AML. *Clin Adv Hematol Oncol*. 2011;9:948-951.
2. Meijer E, Cornelissen JJ. Allogeneic stem cell transplantation in acute myeloid leukemia in first or subsequent remission: weighing prognostic markers predicting relapse and risk factors for non-relapse mortality. *Semin Oncol*. 2008;35:449-457.
3. Koreth J, Schlenk R, Kopecky KJ, et al. Allogeneic stem cell transplantation for acute myeloid leukemia in first complete remission: systematic review and meta-analysis of prospective clinical trials. *JAMA*. 2009;301:2349-2361.
4. Sorror ML, Sandmaier BM, Storer BE, et al. Comorbidity and disease status based risk stratification of outcomes among patients with acute myeloid leukemia or myelodysplasia receiving allogeneic hematopoietic cell transplantation. *J Clin Oncol*. 2007;25:4246-4254.
5. Ruggeri L, Capanni M, Urbani E, et al. Effectiveness of donor natural killer cell alloreactivity in mismatched hematopoietic transplants. *Science*. 2002;295:2097-2100.
6. Cooley S, Trachtenberg E, Bergemann TL, et al. Donors with group B KIR haplotypes improve relapse-free survival after unrelated hematopoietic cell transplantation for acute myelogenous leukemia. *Blood*. 2009;113:726-732.
7. Weiden PL, Flournoy N, Thomas ED, et al. Antileukemic effect of graft-versus-host disease in human recipients of allogeneic-marrow grafts. *N Engl J Med*. 1979;300:1068-1073.
8. Horowitz MM, Gale RP, Sondel PM, et al. Graft-versus-leukemia reactions after bone marrow transplantation. *Blood*. 1990;75:555-562.
9. Valcárcel D, Martino R, Caballero D, et al. Sustained remissions of high-risk acute myeloid leukemia and myelodysplastic syndrome after reduced-intensity conditioning allogeneic hematopoietic transplantation: chronic graft-versus-host disease is the strongest factor improving survival. *J Clin Oncol*. 2008;26:577-584.
10. Pérez-Simón JA, Díez-Campelo M, Martino R, et al. Influence of the intensity of the conditioning regimen on the characteristics of acute and chronic graft-versus-host disease after allogeneic transplantation. *Br J Haematol*. 2005;130:394-403.
11. Mackinnon S, Barnett L, Heller G, O'Reilly RJ. Minimal residual disease is more common in patients who have mixed t-cell chimerism after bone marrow transplantation for chronic myelogenous leukemia. *Blood*. 1994;83:3409-3416.
12. Mackinnon S, Papadopoulos EB, Carabasi MH, et al. Adoptive immunotherapy evaluating escalating doses of donor leukocytes for relapse of chronic myeloid leukemia after bone marrow transplantation: separation of graft-versus-leukemia responses from graft-versus-host disease. *Blood*. 1995;86:1261-1268.
13. Baron F, Baker JE, Storb R, et al. Kinetics of engraftment in patients with hematologic malignancies given allogeneic hematopoietic cell transplantation after nonmyeloablative conditioning. *Blood*. 2004;104:2254-2262.
14. Mohty M, Avinens O, Faucher C, Viens P, Blaise D, Eliaou J-F. Predictive factors and impact of full donor T-cell chimerism after reduced intensity conditioning allogeneic stem cell transplantation. *Haematologica*. 2007;92:1004-1006.
15. Valcárcel D, Martino R, Caballero D, et al. Chimerism analysis following allogeneic peripheral blood stem cell transplantation with reduced-intensity conditioning. *Bone Marrow Transplant*. 2003;31:387-392.
16. Schmid C, Labopin M, Nagler A, et al. Donor lymphocyte infusion in the treatment of first hematological relapse after allogeneic stem-cell transplantation in adults with acute myeloid leukemia: a retrospective risk factors analysis and comparison with other strategies by the EBMT acute leukemia working party. *J Clin Oncol*. 2007;25:4938-4945.
17. Collins RH, Shpilberg O, Drobyski WR, et al. Donor leukocyte infusions in 140 patients with relapsed malignancy after allogeneic bone marrow transplantation. *J Clin Oncol*. 1997;15:433-444.
18. Kolb HJ, Schattenberg A, Goldman JM, et al. Graft-versus-leukemia effect of donor lymphocyte transfusions in marrow grafted patients. *Blood*. 1995;86:2041-2050.
19. Choi S-J, Lee J-H, Lee J-H, et al. Treatment of relapsed acute myeloid leukemia after allogeneic bone marrow transplantation with chemotherapy followed by G-CSF-primed donor leukocyte infusion: a high incidence of isolated extramedullary relapse. *Leukemia*. 2004;18:1789-1797.
20. Schmid C, Schleuning M, Ledderose G, Tischer J, Kolb H-J. Sequential regimen of chemotherapy, reduced-intensity conditioning for allogeneic stem-cell transplantation, and prophylactic donor lymphocyte transfusion in high-risk acute myeloid leukemia and myelodysplastic syndrome. *J Clin Oncol*. 2005;23:5675-5687.
21. Peggs KS, Thomson K, Hart DP, et al. Dose-escalated donor lymphocyte infusions following reduced intensity transplantation: toxicity, chimerism, and disease responses. *Blood*. 2004;103:1548-1556.
22. Orti G, Lowdell M, Fielding A, et al. Phase I study of high-stringency CD8 depletion of donor leukocyte infusions after allogeneic hematopoietic stem cell transplantation. *Transplantation*. 2009;88:1312-1318.
23. Meyer RG, Wagner EM, Konur A, et al. Donor CD4 T cells convert mixed to full donor T-cell chimerism and replenish the CD52-positive T-cell pool after alemtuzumab-based T-cell-depleted allo-transplantation. *Bone Marrow Transplant*. 2010;45:668-674.
24. Schnittger S, Schoch C, Kern W, et al. Nucleophosmin gene mutations are predictors of favorable prognosis in acute myelogenous leukemia with a normal karyotype. *Blood*. 2005;106:3733-3739.
25. Döhner K, Schlenk RF, Habdank M, et al. Mutant nucleophosmin (NPM1) predicts favorable prognosis in younger adults with acute myeloid leukemia and normal cytogenetics: interaction with other gene mutations. *Blood*. 2005;106:3740-3746.
26. Krönke J, Schlenk RF, Jensen K-O, et al. Monitoring of minimal residual disease in NPM1-mutated acute myeloid leukemia: a study from the German-Austrian acute myeloid leukemia study group. *J Clin Oncol*. 2011;29:2709-2716.
27. Bacher U, Badbaran A, Fehse B, Zabelina T, Zander AR, Kröger N. Quantitative monitoring of NPM1 mutations provides a valid minimal residual disease parameter following allogeneic stem cell transplantation. *Exp Hematol*. 2009;37:135-142.
28. Foran JM. New prognostic markers in acute myeloid leukemia: perspective from the clinic. *Hematology Am Soc Hematol Educ Program*. 2010;2010:47-55.
29. DeZern AE, Sung A, Kim S, et al. Role of allogeneic transplantation for FLT3/ITD acute myeloid leukemia: outcomes from 133 consecutive newly diagnosed patients from a single institution. *Biol Blood Marrow Transplant*. 2011;17:1404-1409.
30. Cilloni D, Saglio G, WT1 as a universal marker for minimal residual disease detection and quantification in myeloid leukemias and in myelodysplastic syndrome. *Acta Haematol*. 2004;112:79-84.
31. Keilholz U, Menses HD, Gaiger A, et al. Wilms' tumour gene 1 (WT1) in human neoplasia. *Leukemia*. 2005;19:1318-1323.
32. Cilloni D, Renneville A, Hermitte F, et al. Real-time quantitative polymerase chain reaction detection of minimal residual disease by standardized WT1 assay to enhance risk stratification in acute myeloid leukemia: a European leukemianet study. *J Clin Oncol*. 2009;27:5195-5201.
33. Weisser M, Kern W, Rauhut S, et al. Prognostic impact of RT-PCR-based quantification of WT1 gene expression during MRD monitoring of acute myeloid leukemia. *Leukemia*. 2005;19:1416-1423.
34. Candoni A, Toffoletti E, Gallina R, et al. Monitoring of minimal residual disease by quantitative WT1 gene expression following reduced intensity conditioning allogeneic stem cell transplantation in acute myeloid leukemia. *Clin Transplant*. 2011;25:308-316.
35. Lange T, Hubmann M, Burkhardt R, et al. Monitoring of WT1 expression in PB and CD34(+) donor chimerism of BM predicts early relapse in AML and MDS patients after hematopoietic cell transplantation with reduced-intensity conditioning. *Leukemia*. 2011;25:498-505.
36. Walter RB, Gooley TA, Wood BL, et al. Impact of pretransplantation minimal residual disease, as detected by multiparametric flow cytometry, on outcome of myeloablative hematopoietic cell transplantation for acute myeloid leukemia. *J Clin Oncol*. 2011;29:1190-1197.
37. Bosi A, Laszlo D, Labopin M, et al. Second allogeneic bone marrow transplantation in acute leukemia: results of a survey by the European cooperative group for blood and marrow transplantation. *J Clin Oncol*. 2001;19:3675-3684.
38. Michallet M, Tanguy ML, Socié G, et al. Second allogeneic haematopoietic stem cell transplantation in relapsed acute and chronic leukaemias for patients who underwent a first allogeneic bone marrow transplantation: a survey of the Société Française de Greffe de Moelle (SFGM). *Br J Haematol*. 2000;108:400-407.
39. Eapen M, Giralt SA, Horowitz MM, et al. Second transplant for acute and chronic leukemia relapsing after first HLA-identical sibling transplant. *Bone Marrow Transplant*. 2004;34:721-727.
40. Shaw BE, Mufti GJ, Mackinnon S, et al. Outcome of second allogeneic transplants using reduced-intensity conditioning following relapse of haematological malignancy after an initial allogeneic transplant. *Bone Marrow Transplant*. 2008;42:783-789.