

# Relapsed Diffuse Large B-Cell Lymphoma—10 Years Later

Shikha Jain, MD  
Neel Shah, MD  
Stephanie Gregory, MD

*Rush University Medical Center, Chicago, Illinois*

## Introduction

Diffuse large B-cell lymphoma (DLBCL) is the most common subtype of non-Hodgkin lymphoma (NHL), and it accounts for approximately 25% of NHL cases.<sup>1</sup> The incidence of DLBCL in the United States is approximately 7 cases per 100,000 person-years, with a male predominance.<sup>2</sup> Caucasian Americans have higher rates than African Americans, Asians, and American Indians, in order of decreasing incidence. Incidence increases with age, with a median age of presentation of 64 years.<sup>3,4</sup> There also appears to be a familial aggregation of patients with DLBCL and other NHL subtypes. A large population-based observational study from Sweden and Denmark reported that relatives of probands with aggressive NHL had an approximately 3.5-fold increased risk of developing NHL.<sup>4</sup> DLBCL can occur de novo as well as through the transformation of many different types of low-grade B-cell lymphomas.

Initial evaluation for treatment options in patients with DLBCL depends on the precise histologic subtype, the extent and sites of disease, and the performance status of the patient. Advanced disease is traditionally defined as Ann Arbor stage III or IV and accounts for approximately 70% of patients with DLBCL. Ann Arbor stage III indicates that the cancer has spread to both sides of the diaphragm. Ann Arbor stage IV is defined by disseminated involvement of 1 or more extralymphatic organs, including any involvement of the bone marrow, liver, or nodular involvement of the lungs. Advanced stage DLBCL is treated primarily with systemic chemotherapy plus rituximab (Rituxan, Genentech).

Although there have been significant advances in the treatment of patients with DLBCL, relapse can occur. Long-term disease-free survival occurs in at least 50% of patients diagnosed with DLBCL, and when the lymphoma is localized at time of diagnosis, this can reach more than 80% of patients.<sup>5,6</sup> Relapse usually occurs in the first 2–3 years after treatment, and late relapse occurring more than 5 years after treatment is rare.<sup>7</sup> Relapse typically occurs at a different site from initial presentation.<sup>8</sup> Cure rates do differ by age. In this report we describe a patient with relapsed DLBCL 10 years after initial diagnosis and treatment.

## Case

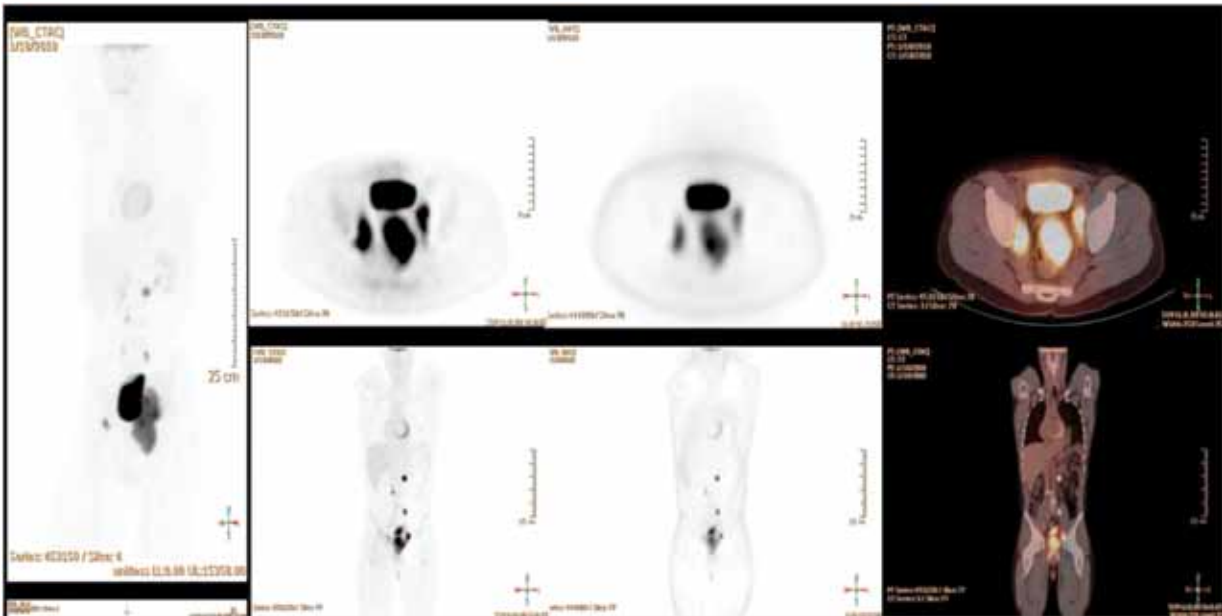
The patient is a 21-year-old man with no medical history who initially presented with episodic left upper back pain. He saw a chiropractor several months after onset of symptoms and had relief of his pain. He was asymptomatic for 5 months when he noticed a small mass on his left anterior chest wall. The patient was not on any medications at the time, and his social history was unremarkable. However, his family history was significant for a paternal grandfather who died of Hodgkin lymphoma and a maternal grandfather with a history of transient ischemic attacks (TIAs). On initial exam, pertinent findings included a 5 × 4.5-cm mass in his left anterior chest wall with no lymphadenopathy or palpable hepatosplenomegaly. Significant laboratory test results included a white blood cell (WBC) count of 11.4, platelet count of 448,000, hemoglobin (Hgb) of 14.1 g/dL, erythrocyte sedimentation rate (ESR) of 45 mm/hr,  $\beta_2$  microglobulin of 1.8, lactate dehydrogenase (LDH) of 889, blood urea nitrogen (BUN) of 18 mg/dL, normal creatinine clearance, and normal liver panel. A computed tomography (CT) scan of the chest, abdomen, and pelvis was done at this time, and it revealed a mediastinal mass measuring 13 × 9 cm, with central necrosis, a

Address correspondence to:  
Shikha Jain, MD, Rush University Medical Center, 1725 West Harrison Street,  
Suite #809, Chicago, IL 60612-3824; Phone: 312-942-7015; Fax: 312-942-  
3192.

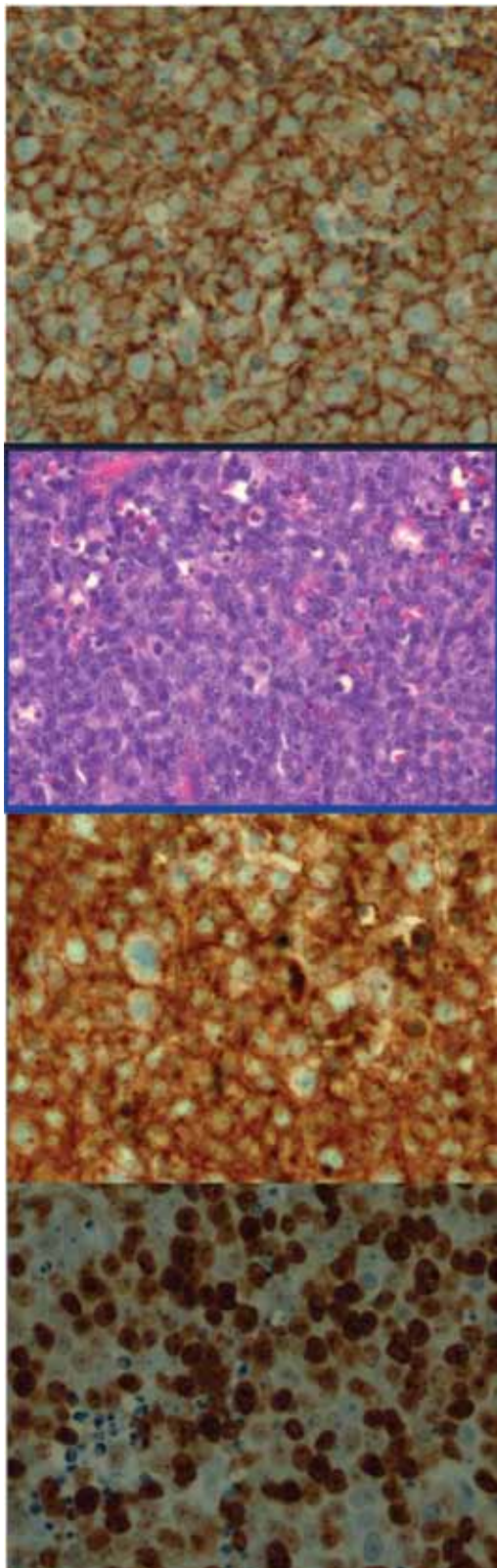
1.5-cm lymph node (LN) in the left paraaortic region, and borderline hepatosplenomegaly. Biopsy of the left anterior chest wall was CD 10/19/20/23/45+, and pathology review was consistent with DLBCL. An echocardiogram showed an ejection fraction (EF) of 50–55%, and the patient did not display any B symptoms. The patient's bone marrow biopsy was negative; his International Prognostic Index (IPI) was 1 at the age of 21 years, his extranodal disease was 0, his LDH was 889, his Eastern Cooperative Oncology Group (ECOG) performance status was 0, and he had stage 1B bulky disease (Figure 1).

The patient was started on a regimen of cyclophosphamide, doxorubicin, vincristine, and prednisone (CHOP) chemotherapy (rituximab was not commercially available at the time). The patient was restaged after 4 cycles with a mid-stage gallium scan, which was negative, and a CT, which showed a 50% decrease in the size of the mediastinal mass. He completed 8 cycles of CHOP chemotherapy, and a follow-up positron emission tomography (PET) scan demonstrated uptake in the mediastinum, thus the patient was referred to the transplant service. He then received 1 dose of rituximab and completed high-dose carmustine, etoposide, cytarabine, and melphalan (BEAM) with autologous stem-cell transplant (SCT). At this time, the patient's mediastinal mass decreased to 6.5 cm, and the patient received a consolidative course of external beam radiation with 3,000 cGY in 20 fractions to the involved fields in the mediastinum. For the next 3

years, the patient had yearly CT and gallium scans, which were negative. The patient was then lost to follow up for approximately 9 years, at which time he returned to have a staging CT scan, which was negative. Five months later, the patient noted that he was developing progressive constipation. The following month he noted a mass in his left groin. On exam he was found to have a 3.7 × 3-cm left groin palpable lymph node with no other significant findings. CT scan showed a 2.9 × 3.7-cm left inguinal lymph node, which had previously been measured to be approximately 0.5 × 0.9 cm, as well as a 1.4 × 1.6-cm right inguinal node, which previously had been measured at 0.3 × 0.7 cm. The CT scan also showed a newly enlarged lymph node in the left para-aortic region that measured 1.5 × 1.7 cm that was previously 0.4 × 0.9 cm, as well as new left external iliac chain lymph nodes measuring 1.6 × 2.0 cm and 1.1 × 1.6 cm. A multigated acquisition (MUGA) scan at this time showed an EF of 52%. PET and CT scan findings were consistent with a metabolically intense lesion in the abdomen involving retroperitoneal, abdominal, celiac, and pelvic lymph nodes (LN) consistent with a neoplasm, presumably lymphoma (Figure 2). An enlarged metabolically active lesion was also seen in the region of the rectum. A colonoscopy showed an erythematous rectum with edematous folds, friability, and an aphthous ulcer. Bone marrow biopsy showed no evidence of disease (NED), and an excisional biopsy of LN again showed DLBCL. Laboratory tests at this time



**Figure 1.** Positron emission tomography/computed tomography (PET/CT) scan.



**Figure 2.** Pathology of diffuse large B-cell lymphoma.

showed a WBC count of 7.4, Hg of 14.9, a platelet count of 218, and an LDH of 280. At this time IPI was 1 at age 30, extranodal disease was 1, LDH count was 280, and the patient had an ECOG performance status of 0 and stage IIE disease (although it was unclear as to whether the mass was arising from the rectum or if this was a nodal mass pushing on the rectum). At this point he has received 2 cycles of rituximab, ifosfamide, carboplatin, and etoposide (R-ICE) and was restaged with CT scans, which showed a marked decrease in tumor burden. The patient is undergoing a second autologous stem cell transplant with cryopreserved cells from 10 years prior.

### Diagnosis

The differential diagnosis of DLBCL includes hematologic malignancies such as other non-Hodgkin and Hodgkin lymphomas. The diagnosis is best made by excisional tissue biopsy, most often of a lymph node. Morphology and immunophenotyping are essential to making the final diagnosis. DLBCL is a heterogeneous group of tumors made up of large transformed B cells with basophilic cytoplasm, prominent nucleoli, diffuse growth pattern, and a greater than 40% proliferation fraction. There is usually complete effacement of the normal lymph node architecture by sheets of atypical lymphoid cells. Tumor cells are larger in size and often resemble normal centroblasts or immunoblasts. The immunophenotype can be confirmed by histochemistry or flow cytometry. DLBCL tumor cells generally express pan-B-cell antigens (CD19, CD20, CD22, CD79a) as well as CD45 and, in many cases, staining for markers CD20 and CD79a is sufficient to make the diagnosis.

At the time of diagnosis, approximately 60% of patients present with advanced-stage DLBCL (stage III or IV), whereas 40% have more localized disease that can be contained within 1 radiation field.<sup>9,10</sup> Extranodal extramedullary disease occurs in up to 40% of cases, with the stomach and gastrointestinal tract being the most common sites of extranodal involvement.<sup>3</sup> However, the disease can arise in virtually any tissue.

Patients with relapsed DLBCL most commonly present within the first 2 or 3 years after treatment, and relapse occurring more than 5 years after initial treatment is rare. A retrospective study performed in Lyon, France, is one of the largest reports of patients with DLBCL who presented with relapse 5 or more years after diagnosis. In the Lyon study, 3.6% of patients with DLBCL relapsed after 5 years.<sup>8</sup> This is consistent with the incidence reported in other studies.<sup>11</sup> Interestingly, in the Lyon study, only 15% of patients with initial localized disease experienced relapse at the same site. Histologically, 83% of these patients had relapse as DLBCL and 17% had relapse as indolent histology (follicular lymphoma, nodal marginal

zone lymphoma, and extranodal mucosal associated lymphoid tissue [MALT] lymphoma). Of the patients with DLBCL relapse, 18% had an associated indolent component. Most patients with late relapse reported in the literature thus far tend to have initial early-stage disease, extranodal involvement, and a favorable IPI.<sup>8</sup>

### Clinical Characteristics

Patients with DLBCL often present with a rapidly enlarging symptomatic mass such as in our patient, and this nodal enlargement usually involves the neck or abdomen. Approximately 30% of patients present with systemic B symptoms such as fever, weight loss, and night sweats, and over 50% of patients present with elevated serum LDH.<sup>12</sup> DLBCL can be extremely invasive and it can result in local compression of vessels (eg, superior vena cava syndrome) or airways (eg, tracheal-bronchial compression), and involvement of bone (eg, cord compression) or peripheral nerves, thus requiring emergent intervention.

The prognosis in DLBCL is associated with the IPI score. This score was created in 1993 to assign prognosis to patients with aggressive NHL undergoing treatment with doxorubicin-containing chemotherapeutic regimens. When calculating the IPI score, 1 point is given to each of the following characteristics: age over 60, serum LDH concentration above normal, ECOG performance status of greater than or equal to 2, Ann Arbor stage III or IV, and number of extranodal disease sites greater than 1. A score of 0–1 places the patient in a low-risk group with a 5-year overall survival (OS) rate of 73% and a complete response (CR) rate of 87%. A score of 2 puts the patient at low-intermediate risk with a 5-year OS rate of 51% and CR rate of 67%; a score of 3 correlates with high-intermediate risk, a 5-year OS rate of 43% and a CR rate of 55%. Finally, a score of 4–5 places the patient in the high-risk group, with a 26% 5-year OS rate and a 44% CR rate.<sup>13</sup> Our patient was in the low-risk group based on the IPI scoring system both at time of initial presentation and at recurrence.

### Discussion

Primary large B-cell lymphoma of the mediastinum (PMBL) comprises 7% of DLBCLs and 2.4% of all NHL cases. PMBL typically affects persons in their third or fourth decade of life. Patients present with a locally invasive anterior mediastinal mass originating in the thymus, often with superior vena cava syndrome and airway compromise. Structures that may be involved by direct extension include the lungs, pleura, and pericardium. At time of diagnosis, a retrospective analysis found the following signs and symptoms: elevated LDH, pleural

or pericardial effusions, and systemic B symptoms such as fevers, night sweats, and weight loss. Relapses tend to be extranodal, occurring in the liver, gastrointestinal tract, kidneys, ovaries, and central nervous system. Studies have reported cure rates similar to those for typical DLBCL with aggressive chemotherapy and mediastinal irradiation. If progression or relapse occurs, salvage therapy is rarely curative.

A retrospective study of patients from 2 centers in Lyon, France between 1985 and 2003 looked at patients with DLBCL who suffered a relapse. The study included 54 patients with a median age of 57 years. Forty-four of the patients (81%) had DLBCL histology at the time of relapse, and 10 patients (19%) had an indolent histology. Of these patients, 63% were stage I–II (34 patients), 84% had a low or low intermediate IPI (41 patients), and 66% had extranodal involvement (35 patients). Immunohistochemistry (IHC) at diagnosis was germinal center B cell (GCB) in 57% (12/21) and non-GCB in 43% (9/21). Forty-seven of 53 patients received CHOP and doxorubicin/cyclophosphamide/vindesine/bleomycin/prednisone (ACVBP)-like regimens. One patient underwent autologous transplantation, and 1 patient received rituximab. The median time from diagnosis to relapse was 7.4 years (range, 5–20.5 years). Clinical characteristics at relapse included a median age of 66 years, stage I/II disease in 48% (26/54) of patients, and extranodal involvement in 73% (31/43) of patients. Treatment at relapse included rituximab in 21 of 54 patients and autologous SCT in 15 of 54 patients, with 7 patients receiving both. Estimated 5-year rates of event-free survival (EFS) and OS after relapse were 25% and 35% for all patients. Patients with DLBCL histology at relapse had estimated 5-year EFS and OS rates of 18% and 28%, respectively. The findings of this study, presented at the 2009 American Society of Clinical Oncology meeting, revealed that patients with DLBCL who suffered late relapse presented with localized stage, favorable IPI, and extranodal involvement. However, even if initial characteristics at time of first treatment were favorable, the outcome of patients with DLBCL at the time of relapse remains poor, and aggressive treatment such as autologous SCT should be pursued whenever possible.<sup>8</sup> In the CORAL (Collaborative Trial in Relapsed Aggressive Lymphoma) study, R-ICE was compared to rituximab, dexamethasone, aracytine, and cisplatin (R-DHAP). Patients included in the study were those with CD20-positive DLBCL who presented with initial relapse or those who failed first-line therapy. These patients were randomized into the R-DHAP group or the R-ICE group. Patients who responded received BEAM and autologous SCT and were then randomized into either the observation group or the group receiving 1 year of rituximab for maintenance. The results of this intent-to-treat analysis were based on the first 396 patients randomized in 11 countries (R-ICE, n=202; R-DHAP, n=194). The median



age was 55 years. In 225 patients, relapse occurred after 12 months, and 166 patients were refractory to treatment or suffered early relapse. Of those included, 244 patients had prior exposure to rituximab, and these patients were found to have more refractory disease and adverse prognostic factors. Our patient only had 1 infusion with BEAM. There was no difference in response rates between R-ICE (63.5%) and R-DHAP (62.8%). Autologous SCT was performed in 206 patients. The factors that significantly affected response ( $P < .0001$ ) were refractory/relapse of less than 12 months (46% vs 88%) and secondary IPI greater than 1 (52% vs 71%). There was not a significant difference between R-ICE and R-DHAP for 3-year EFS (26% vs 35%;  $P = .6$ ) and OS (47% vs 51%;  $P = .5$ ). Three-year EFS was affected by prior treatment with rituximab versus no prior treatment (21% and 47%, respectively;  $P < .0001$ ), early relapse less than 12 months versus more than 12 months (20% vs 45%, respectively;  $P < .0001$ ), and secondary IPI of 2–3 vs 0–1 (18% vs 40%, respectively;  $P = .0001$ ). In the Cox model, all of these parameters are statistically significant ( $P < .0001$ ) for EFS, PFS, and OS. This study concluded that there was no difference between R-ICE and R-DHAP. In patients without adverse prognostic factors, a response rate of greater than 80% was observed. However, patients with early relapse or patients refractory to upfront rituximab-based chemotherapy had a poor response rate and prognosis.<sup>14,15</sup>

## Conclusions

Current data on the role of allogeneic SCT and reduced-intensity conditioning (RIC) allogeneic SCT for patients with poor-risk DLBCL is very limited. Comparative studies of autologous and allogeneic SCT for aggressive NHL have failed to show a survival advantage for allogeneic SCT. This is despite the observation of lower relapse rates in patients undergoing allogeneic SCT compared with those undergoing autologous SCT. This lower response has usually been offset by the higher transplant-related mortality associated with allogeneic SCT. At present, there is no clear evidence of a clinically significant graft-versus-lymphoma effect in DLBCL.

There is also a paucity of data on DLBCL patients who present with late (greater than 5 years) relapse. The most optimal treatment regimen is not known, although salvage chemotherapy followed by transplant is currently the most commonly used approach. Over the last few years, the use of bendamustine (Treanda, Cephalon), a unique cytotoxic agent with antimetabolite and alkylating properties, has grown in popularity in the United States. In 2008, it was approved by the FDA for the treatment of CLL and rituximab-refractory indolent B-cell NHL. Approval was based on the results of a multicenter, single-arm trial. In

this study, bendamustine demonstrated significant efficacy, with an overall response rate of 75%, median PFS of 9.3 months, and a median duration of response of 9.2 months. In general, it was tolerated fairly well, though over half of the patients developed grade 3/4 neutropenia, and one fifth of patients developed grade 3/4 infections.<sup>16</sup> Each approach should be individualized and tailored to the specific patient. Further research is still needed to determine the optimal treatment plan for relapsed patients, and enrollment in clinical trials should be encouraged whenever possible.

## References

1. Swerdlow S, Campo E, Harris NL, et al. *World Health Organization Classification of Tumours of Haematopoietic and Lymphoid Tissues*. Lyon, France; IARC: 2008.
2. Morton L, Wang SS, Devesa SS, Hartge P, Weisenburger DD, Linet MS. Lymphoma incidence patterns by WHO subtype in the United States. *Blood*. 2006;107:265-276.
3. Moller M, Pedersen NT, Christensen BE. Diffuse large B-cell lymphoma: clinical implications of extranodal versus nodal presentation—a population-based study of 1575 cases. *Br J Haematol*. 2004;124:151-159.
4. Goldin L, Landgren O, McMaster ML, et al. Familial aggregation and heterogeneity of non-Hodgkin lymphoma in population-based samples. *Cancer Epidemiol Biomarkers Prev*. 2005;14:2402-2406.
5. Feugier P, Van Hoof A, Sebban C, et al. Long-term results of the R-CHOP study in the treatment of elderly patients with diffuse large B-cell lymphoma: a study by the Groupe d'Etude des Lymphomes de l'Adulte. *J Clin Oncol*. 2005;23:4117-4126.
6. Reyes F, Lepage E, Ganem G, et al. ACVBP versus CHOP plus radiotherapy for localized aggressive lymphoma. *N Engl J Med*. 2005;352:1197-1205.
7. Damaj G, Bernard M, Legouill S, et al. Late relapse of localized high-grade non-Hodgkin's lymphoma: Clinical and biological features. *Blood* (ASH Annual Meeting Abstracts). 2008;112: Abstract 2603.
8. Larouche JF, Berger F, Chassagne-Clément C, et al. Lymphoma recurrence 5 years or later following diffuse large B-cell lymphoma: clinical characteristics and outcome. *J Clin Oncol*. 2010;28:2094-2100.
9. Rudders R, Ross M, DeLellis R. Primary extranodal lymphoma: response to treatment and factors influencing prognosis. *Cancer*. 1978;42:406-416.
10. Paryani S, Hoppe R, Burke J, et al. Extranodal involvement in diffuse non-Hodgkin's lymphoma. *J Clin Oncol*. 1983;1:682-688.
11. Ko AH, Yuen AR. Clinical outcomes associated with very late relapses in diffuse large cell lymphoma. *Leuk Lymphoma*. 2002;43:1789-1793.
12. Armitage JO, Weisenburger DD. New approach to classifying Non-Hodgkin's lymphomas: Clinical features of the major histologic subtypes. *J Clin Oncol*. 1998;16:2780-2795.
13. A predictive model for aggressive non-Hodgkin's lymphoma. The International Non-Hodgkin's Lymphoma Prognostic Factors Project. *N Engl J Med*. 1993;329:987-994.
14. Hagberg H, Gisselbrecht C; CORAL study group. Randomised phase III study of R-ICE versus R-DHAP in relapsed patients with CD20 diffuse large B-cell lymphoma (DLBCL) followed by high-dose therapy and a second randomisation to maintenance treatment with rituximab or not: an update of the CORAL study. *Ann Oncol*. 2006;Suppl 4:iv31-32.
15. Gisselbrecht C, Glass B, Mounier N, et al. Salvage Regimens With Autologous Transplantation for Relapsed Large B-Cell Lymphoma in the Rituximab Era. *J Clin Oncol*. 2010;28:4184-4190.
16. Ujjani C, Cheson B. Efficacy of Bendamustine in Rituximab-refractory Indolent B-cell non-Hodgkin lymphoma: review of a pivotal trial. *Future Oncology*. 2011;7:9-14.

# Review

## Late Relapses in Diffuse Large B-Cell Lymphoma

Lisa M. Baumann Kreuziger, MD,<sup>1</sup>  
and Vicki A. Morrison, MD<sup>1,2</sup>

<sup>1</sup>*Division of Hematology, Oncology, and Transplant,  
University of Minnesota, Minneapolis, MN;*

<sup>2</sup>*Veterans Affairs Medical Center, Minneapolis, MN*

Jain and colleagues<sup>1</sup> describe a 21-year-old patient with stage IB diffuse large B-cell lymphoma (DLBCL) who presented with a 13 × 9-cm mediastinal mass. He was treated with 8 cycles of cyclophosphamide, doxorubicin, vincristine, and prednisone (CHOP), with a partial response. Autologous transplant after high-dose carmustine, cytarabine, etoposide, and melphalan (BEAM) conditioning reduced his mass further, and he received consolidative radiation therapy to the residual tumor. Biopsy-proven relapse occurred 12.5 years later in abdominal, retroperitoneal, and inguinal lymph nodes. He received additional salvage chemotherapy (rituximab, ifosfamide, carboplatin, etoposide) and an autologous transplant. The patient's long remission duration prior to relapse and his unique initial presentation are interesting points for discussion.

### Timing of Relapse in DLBCL

For patients with DLBCL, the International Prognostic Index (IPI) is the most predictive of outcomes. Overall survival based on IPI has been noted by Jain and colleagues,<sup>1</sup> and alterations of the IPI based on age and early stage have also been used. A revised IPI score using patients treated with rituximab (Rituxan, Genentech) condensed the risk factors from the IPI (age >60 years, stage III/IV, elevated lactate dehydrogenase, performance status  $\geq 2$ , and  $\geq 1$  extranodal site of disease) into very good (0 risk factors), good (1–2 risk factors), or poor (3–5 risk factors) prognostic groups.<sup>2</sup> Other studies suggest that rituximab improves outcomes in any IPI group, thus retaining prognostic significance.<sup>3</sup>

The vast majority of relapses in DLBCL occur within the first 2–3 years after completion of induction therapy. Late relapse is not universally defined, but it could be considered to be that which occurs 5 years or more after treatment is completed.

Several prospective trials of patients treated with CHOP versus rituximab plus CHOP (R-CHOP) have

long-term follow-up data available to address the timing of relapse. A US Intergroup study enrolled patients of at least 60 years of age, and included a second randomization of rituximab maintenance therapy every 6 months.<sup>4</sup> Untreated patients were randomized to R-CHOP (n=318) or CHOP (n=314) given every 21 days. Rituximab was administered 7 and 3 days prior to cycle 1 and 2 days prior to cycles 3, 5, and 7. Patients were assessed after 4 cycles of therapy for response and received 2 cycles of chemotherapy after complete remission. Patients achieving partial or complete remissions (n=415) were then randomized to observation (n=208) or maintenance rituximab (n=207) given as 4 weekly doses every 6 months. After a median of 6 years of follow-up, there were 253 deaths in eligible/evaluable patients.<sup>3</sup> Of these deaths, 26% of CHOP-treated patients and 21% of R-CHOP-treated patients died due to their lymphoma. Deaths related to disease were most common overall, especially in the first 2 years. With 9.4 years of follow-up from induction therapy, failure-free survival (FFS; composed of relapse, non-protocol treatment, or death) was 35% in patients treated with R-CHOP and 25% in the CHOP group<sup>4</sup>—this is 18% and 21% less than the 3.5-year FFS, respectively. When the timing of treatment failure was examined, it was found that 57% of the R-CHOP treated patients and 67% of the CHOP-treated patients experienced treatment failure within the first 2 years of follow-up. Late failures, specifically those that occurred 5 or more years after randomization, were seen in 18% of the R-CHOP-treated patients, and 16% of those receiving CHOP.<sup>5</sup>

Long-term follow-up from a similar study from the Groupe d'Etude des Lymphomes de l'Adulte (GELA) found that 40% of patients in the R-CHOP and 63% of patients in the CHOP arm had progressive disease.<sup>5</sup> Patients aged 60–80 years were randomized to receive 8 cycles of CHOP (n=197) given every 21 days or R-CHOP (n=202) with rituximab administered on day 1. In this trial, 87% of relapses occurred within the first 3 years (83% R-CHOP, 90% CHOP relapses). However, 7% of relapses occurred after 5 years (10% in the R-CHOP arm, 5% in the CHOP arm).<sup>6</sup>

In the NHL-B2 trial of the German High-Grade Non-Hodgkin's Lymphoma Study Group, 689 aggressive lymphoma patients aged 61–75 years were randomized to 6 cycles of therapy with CHOP every 14 days (CHOP-14) or 21 days (CHOP-21) with or without etoposide (administered days 1–3). Event-free survival (EFS; composed of disease progression, initiation of salvage or off-protocol therapy, relapse, or death) at 5 years was 33% for CHOP-21 and 44% for CHOP-14. Patients treated with etoposide had a similar EFS as CHOP-14 with an increase in toxicity. It was found that of the 25 deaths occurring after a median observation of at least 50 months, only 9 were disease-related.<sup>7</sup> Another study comparing treatment intervals was RICOVER-60 (Six Versus Eight Cycles of Bi-Weekly CHOP-14 With or Without Rituximab in

Address correspondence to:

Vicki A. Morrison, MD, VA Medical Center Hematology/Oncology (111E), One Veterans Dr, Minneapolis, MN 55417; Phone: (612) 725-2000; Fax: (612) 725-2149  
E-mail: morri002@umn.edu.

Elderly Patients With Aggressive CD20+ B-Cell Lymphomas), which involved 1,222 patients aged 61–80 years. Three-year EFS (defined as in NHL-B2) was 47% for 6 cycles of CHOP-14, 53% for 8 cycles of CHOP-14, 67% after 6 cycles of R-CHOP-14, and 63% after 8 cycles of R-CHOP-14.<sup>8</sup> Data from both of these trials regarding late relapses is likely forthcoming and will add to our knowledge of whether altering treatment intervals will change the timing of relapse.

In contrast to these trials, the patient presented in this case study was young and had lower risk disease. The Mabthera International Trial (MInT) Group examined the use of CHOP-like regimens with or without rituximab in younger patients with low-risk DLBCL.<sup>9</sup> Patients with IPI 1 disease accounted for 56–58% of those enrolled, in comparison to 26% in the US Intergroup Trial and 12–14% in the GELA study. The rate of events (failure to achieve CR, progressive disease, relapse, death, or additional therapy) after 5 years in the MInT trial was 2.9% in patients treated with CHOP-like regimens and 2.2% in patients treated with rituximab, which is significantly less than the US Intergroup or GELA trials.

In summary, these studies suggest that late relapses occur with increased frequency in older patients with higher risk disease in comparison to patients with low-risk disease. In addition, there appears to be no clear plateau in survival endpoints among the large trials in the elderly, implying a continuous pattern of relapse.

### Primary Mediastinal B-Cell Lymphoma

As the patient described in this case had bulky mediastinal disease and was only 21 years of age at diagnosis, the question arises of whether he had actually developed a primary mediastinal B-cell lymphoma (PMBCL). This is a unique clinical-pathologic subtype of DLBCL, which accounts for 6–13% of all DLBCL.<sup>10</sup> PMBCL tends to occur in younger patients (median age, 30–40 years) with a female predominance.<sup>11</sup> Patients with PMBCL present with bulky disease that becomes symptomatic due to invasion into adjacent organs or pressure on neurovascular structures. Histologically, the tumor is composed of large B cells with bands of sclerosis. The malignant cells are usually positive for B-cell markers including C19, CD20, CD22, and CD45, and negative for CD10, CD21, and HLA-DR.<sup>11</sup> The molecular markers reported for the patient in this case would be consistent with PMBCL.

Due to the uncommon occurrence of PMBCL, treatment recommendations are based upon retrospective reviews and several randomized studies. Combination regimens such as methotrexate, leucovorin, doxorubicin, cyclophosphamide, vincristine, prednisone, bleomycin (MACOP-B) and vincristine substituted for methotrexate in MACOP-B (VACOP-B) have been shown to result in up to an 80% complete response rate, with a 76% 5-year overall survival.<sup>10</sup> In a

recently published subgroup analysis of the MInT trial, there were 87 patients with PMBCL who received CHOP or R-CHOP therapy in approximately equal numbers. The addition of rituximab increased complete response rates from 54% to 80%. Three-year overall survival rates were 83% in the PMBCL patients. Three relapses were reported, the latest of which was 3.5 years after randomization.<sup>12</sup> Maturing of the studies would be necessary to understand the likelihood of late relapse. Given the paucity of randomized data, an anthracycline-containing regimen should be utilized, with consideration for addition of rituximab, in patients with PMBCL.

### Conclusions

Relapse in DLBCL patients occurs most often within the first 2–3 years of diagnosis; however, relapses may occur after 5 years in 2–18% of patients. Patients with higher IPI scores are at greater risk of relapse. PMBCL is a subset of DLBCL that has a relatively good prognosis. Physicians should include PMBCL in the differential diagnosis of young patients with a bulky mediastinal mass.

### References

1. Jain S SN, and Gregory S. Relapsed diffuse large B-cell lymphoma—10 years later. *Clin Adv Hematol Oncol*. 2011;9:704-708.
2. Sehn LH, Berry B, Chhanabhai M, et al. The revised International Prognostic Index (R-IPI) is a better predictor of outcome than the standard IPI for patients with diffuse large B-cell lymphoma treated with R-CHOP. *Blood*. 2007;109:1857-1861.
3. Ziepert M, Hasenclever D, Kuhnt E, et al. Standard International Prognostic Index remains a valid predictor of outcome for patients with aggressive CD20+ B-cell lymphoma in the rituximab era. *J Clin Oncol*. 2010;28:2373-2380.
4. Habermann TM, Weller EA, Morrison VA, et al. Rituximab-CHOP versus CHOP alone or with maintenance rituximab in older patients with diffuse large B-cell lymphoma. *J Clin Oncol*. 2006;24:3121-3127.
5. Morrison VA HF, Habermann TM. R-CHOP versus (vs) CHOP followed by maintenance rituximab (MR) vs observation in older diffuse large B-cell lymphoma (DLBCL) patients: long-term follow-up of Intergroup E4494/C9793. *Blood* (ASH Annual Meeting Abstracts). 2010;116: Abstract 589.
6. Coiffier B, Thieblemont C, Van Den Neste E, et al. Long-term outcome of patients in the LNH-98.5 trial, the first randomized study comparing rituximab-CHOP to standard CHOP chemotherapy in DLBCL patients: a study by the Groupe d'Etudes des Lymphomes de l'Adulte. *Blood* (ASH Annual Meeting Abstracts). 2010;116:2040-2045.
7. Pfreundschuh M, Trumper L, Kloess M, et al. Two-weekly or 3-weekly CHOP chemotherapy with or without etoposide for the treatment of elderly patients with aggressive lymphomas: results of the NHL-B2 trial of the DSHNHL. *Blood*. 2004;104:634-641.
8. Pfreundschuh M, Schubert J, Ziepert M, et al. Six versus eight cycles of bi-weekly CHOP-14 with or without rituximab in elderly patients with aggressive CD20+ B-cell lymphomas: a randomised controlled trial (RICOVER-60). *Lancet Oncol*. 2008;9:105-116.
9. Pfreundschuh M, Trumper L, Osterborg A, et al. CHOP-like chemotherapy plus rituximab versus CHOP-like chemotherapy alone in young patients with good-prognosis diffuse large-B-cell lymphoma: a randomised controlled trial by the MabThera International Trial (MInT) Group. *Lancet Oncol*. 2006;7:379-391.
10. Todeschini G, Secchi S, Morra E, et al. Primary mediastinal large B-cell lymphoma (PMLBCL): long-term results from a retrospective multicentre Italian experience in 138 patients treated with CHOP or MACOP-B/VACOP-B. *Br J Cancer*. 2004;90:372-376.
11. Faris JE, LaCasce AS. Primary mediastinal large B-cell lymphoma. *Clin Adv Hematol Oncol*. 2009;7:125-133.
12. Rieger M, Osterborg A, Pettengell R, et al. Primary mediastinal B-cell lymphoma treated with CHOP-like chemotherapy with or without rituximab: results of the Mabthera International Trial Group study. *Ann Oncol*. 2011;22:664-670.