

# An Epstein-Barr Virus–Associated Smooth Muscle Tumor Successfully Treated with Surgical Resection: A Case Report and Literature Review

Iva Cela, MD<sup>1</sup>  
 Neel B. Shah, MD<sup>1</sup>  
 Dawn Bradly, MD<sup>2</sup>  
 Jerome Loew, MD<sup>2</sup>  
 William Leslie, MD<sup>1</sup>

<sup>1</sup>*Division of Hematology, Oncology, and Stem Cell Transplantation;* <sup>2</sup>*Department of Pathology, Rush University Medical Center, Chicago, IL*

**E**pstein-Barr virus–associated smooth muscle tumors (EBV-SMTs) occur predominantly in immunocompromised patients, either in the setting of solid organ transplantation or with HIV/AIDS.<sup>1</sup> The role of EBV in the development of smooth muscle tumors was first described in the 1990s, after studies consistently showed high levels of EBV replication, EBV in-situ hybridization positivity (EBV encoded RNA [EBER]), and expression of viral genes in neoplastic cells.<sup>2-4</sup> A small number of cases of EBV-SMTs have been reported in adults, but it is the second most common malignancy seen in children with AIDS.<sup>3-6</sup> Typically, the disease has an indolent course, is locally invasive, and is rarely the cause of death.<sup>3,7</sup> Treatment options include surgical resection, radiation therapy, chemotherapy, or improvement of the immune system with highly active antiretroviral therapy (HAART) in patients with HIV/AIDS. Another option in post-transplantation patients is changing the immunosuppressive therapy to sirolimus (Rapamune, Wyeth). No studies have been done to compare these treatment modalities, and a standard approach remains undefined. We report a case of an EBV-SMT presenting as a superficial pelvic soft tissue mass in a patient with AIDS, which was successfully treated with surgical resection alone.

## Case Report

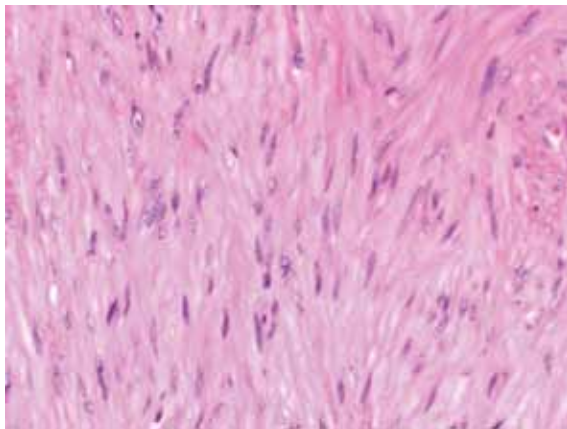
The patient is a 66-year-old African American man who was first diagnosed with HIV/AIDS in 2003 when he presented with Kaposi Sarcoma (KS) lesions on the trunk and face. His CD4+ T-cell count at that time was 14/mm<sup>3</sup>

and the HIV RNA viral load was 16,600 copies/mL. The patient was placed on a regimen of HAART using epivir 150 mg daily, kaetra 4 tablets twice daily, and sustiva 600 mg nightly. Systemic chemotherapy with liposomal doxorubicin was started for KS. The chemotherapy was changed several years later, after the patient developed a decrease in the left ventricular ejection fraction. He then received paclitaxel, which resulted in a nearly complete disappearance of his lesions. He was started on prophylactic therapy for *Pneumocystis carinii pneumonia* (PCP) and *Mycobacterium avium intracellulare* (MAC) with bactrim and zithromax. Shortly after the initial diagnosis of HIV/AIDS, the patient developed multiple opportunistic infections, including disseminated MAC, cryptococcal meningitis, cytomegalovirus (CMV) retinitis, and severe *Candida* esophagitis. The infections were successfully treated. The patient continued to receive HAART, with an eventual decrease in HIV RNA viral load to less than 75 copies/mL by late 2007. His CD4+ T-cell count increased to 88/mm<sup>3</sup>. In early 2008, the patient presented with lethargy, fever, and abdominal pain. A computed tomography scan of the abdomen and pelvis was performed, and the findings included a 2.4-cm, heterogeneous, round, rim-enhancing soft tissue mass located in the subcutaneous fat in the anterior lower pelvis. The physical exam confirmed a firm, nodular, slightly tender mass in that area. No additional lesions or lymphadenopathy were identified on CT scan.

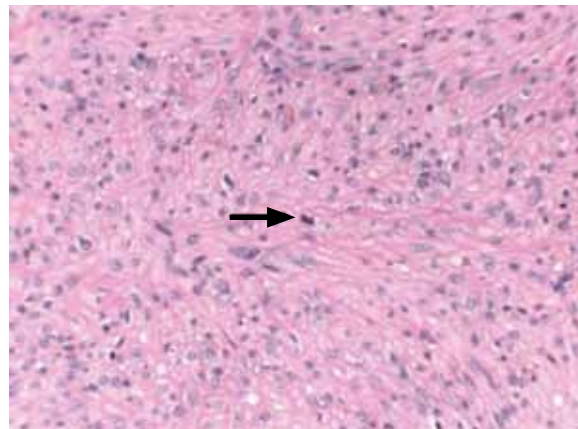
The patient underwent an excisional biopsy of the mass. The gross specimen showed a segment of homogeneous pink-tan soft tissue measuring 2.4 × 1.4 × 1.4 cm without hemorrhage or necrosis. Histologic sections revealed well-differentiated spindle cells arranged in short, intercalating fascicles with eosinophilic cytoplasm and elongated, blunt-ended nuclei displaying mild nuclear atypia (Figure 1). Occasional mitotic figures were

### Address correspondence to:

Neel B. Shah, MD, Division of Hematology/Oncology and SCT, Rush University Medical Center, 1725 West Harrison Street Suite #809, Chicago, IL 60612-3824; Phone: 312-942-7015; Fax: 312-942-3192; E-mail: Neel\_Shah@rush.edu.



**Figure 1.** Spindle cells arranged in short, intercalating fascicles with abundant eosinophilic cytoplasm and elongated, blunt-ended nuclei (40× magnification).



**Figure 2.** Rare mitotic activity, *arrow* (40× magnification).

identified with up to 3 mitoses per 10 high-power fields (Figure 2, *arrow*). Immunohistochemistry was negative for CD31 and CD34, thereby excluding KS. Creatine kinase 8/18, hydroxy-betamethylbutyrate-45, and beta-catenin were also negative, excluding synovial sarcoma, clear cell sarcoma, and desmoid-type fibromatosis, respectively. In addition, sputum was negative for acid fast bacilli (AFB), ruling out Mycobacterium infection, and S100 protein was negative, excluding schwannoma. CD20 staining highlighted rare, scattered B-lymphocytes in the background. The spindle cells stained diffusely and strongly positive for smooth muscle actin (SMA), caldesmon, and EBV in situ hybridization (Figures 3–5). EBV serology showed evidence of past infection, with an EBV viral load of 20,050 copies/mL. After considering the history, histology, and immunohistochemistry, a final diagnosis of EBV-SMT was rendered. Existing HAART was continued, and no further treatment of this neoplasm was initiated. During a follow-up interval of more than 18 months, the patient has continued to experience various infections but has remained free of recurrent EBV-SMT.

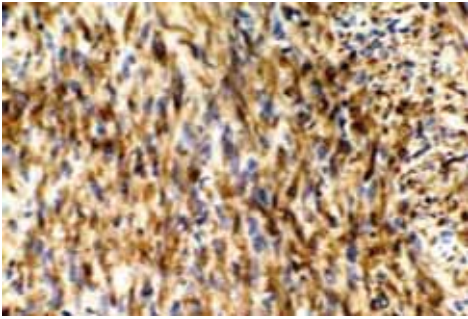
## Discussion

EBV-SMTs are extremely rare and most commonly occur in post-transplantation patients (60%), with AIDS patients being the second most common group.<sup>8</sup> EBV-SMT is the second most frequently occurring malignancy in children with HIV infection. They have a male predominance and occur at unusual sites in adults, including the vocal cords, the cavernous sinus, the chest or abdominal wall, limbs, lungs, bronchi, pleura, pericardium, lymph nodes, orbit, bone, tongue, skin, spleen, gallbladder, small

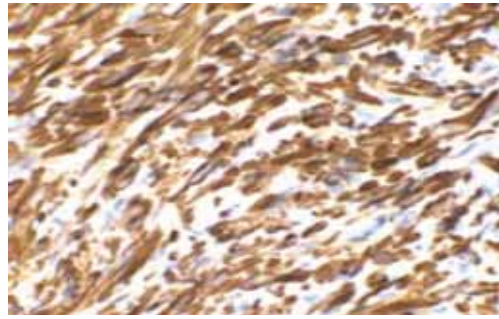
bowel, tonsils, adrenal gland, spinal cord, testes, and soft tissue.<sup>3,9</sup> The liver, brain, spinal cord, and adrenal glands are the most common sites.<sup>3</sup>

The pathogenesis of EBV-SMT is not well understood. Greater than 50% of patients with EBV-SMT present with multiple tumors. Because they are frequently multicentric, there has been a question of whether these neoplasms represent true metastasis versus multiple infectious events. Molecular analysis shows a linear EBV genome that partially circularizes as it enters the cell. This results in a long terminal repeat sequence (LTR) of varied length. The length of the LTR is passed on to descendants of a single infected cell. Therefore, the length of the LTR represents a specific infectious event. In patients with multiple tumors, the length of the LTR varies between tumors at different sites, supporting the idea that multiple tumors represent multiple infectious events rather than metastases from a single neoplastic focus.

Histologic examination shows a dual cell population composed mostly of fusiform-to-spindle shaped cells with areas of small, round cells that stain positive for SMA, caldesmon, and EBER.<sup>3,7,8</sup> The mitotic index is usually low with an average of 3 mitosis per 10 high-power fields, as reported in 2 of the largest case series.<sup>3,7</sup> Deyrup and colleagues has shown a mitotic range of 0–18 mitotic figures per 10 high-power fields.<sup>8</sup> Increasing tumor size, a high degree of cellular atypia, hemorrhage, and necrosis may correlate with malignant potential, but the most important predictor appears to be level of mitotic activity within the tumor.<sup>8</sup> EBV-SMTs do not fit diagnostic criteria for either leiomyoma or leiomyosarcoma. The former are tumors of soft tissue and show almost no mitotic activity, whereas leiomyosarcomas show increased mitotic activity with a high degree of cellular atypia, and



**Figure 3.** Smooth muscle actin (40× magnification).



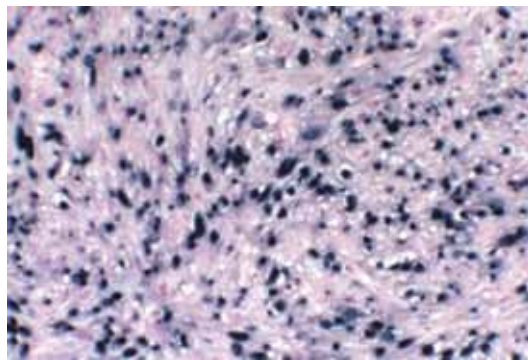
**Figure 4.** Caldesmon (40× magnification).

are highly aggressive and often metastatic.<sup>8</sup> Serology is consistent with past EBV infection but it has no bearing on diagnosis, recurrence monitoring, or burden of disease.<sup>3,6</sup> EBV load itself is not a good predictive marker for EBV-related malignancies in HIV-infected patients.<sup>10</sup>

EBV-SMTs are usually slow growing and locally invasive.<sup>3</sup> Despite the common multifocal presentation of EBV-SMTs, they are rarely fatal.<sup>3,7,8</sup> In a case series of 19 patients, only 1 patient died from the disease.<sup>7</sup> However, there is a report of a renal transplantation patient diagnosed with multifocal liver and lung EBV-SMTs who developed rapid disease progression and subsequently died within 5 months of diagnosis, despite having tumors with a well-differentiated histologic appearance.<sup>11</sup> This particular patient received no surgical or medical intervention.

Surgical resection is first-line therapy for EBV-SMTs, and it may be the only intervention needed in a unifocal tumor. Optimizing HAART to improve immunosuppression may also be helpful. In a case series of 9 AIDS patients with EBV-SMTs—all with CD4+ T-cell counts of less than 200/mm<sup>3</sup>—complete tumor resection and adjuvant radiotherapy were not effective. Complete remission was achieved by surgical resection of unicentric EBV-SMTs followed by HAART in 2 patients.<sup>11</sup> Another study suggested that long-term HAART does not alter EBV DNA load, but leads to restoration of latent-antigen specific cells, reducing EBV reactivation and tumor occurrence.<sup>12</sup> HAART is believed to be more beneficial when started before an irreversible genetic alteration in EBV-infected B-cells has occurred. The prognosis of EBV-SMT malignancies has improved since HAART became available.<sup>12</sup>

Although EBV-SMTs are indolent neoplasms, chemotherapy has been used to treat these tumors.<sup>13</sup> One case report showed a good outcome in an AIDS patient treated with intravenous doxorubicin and dacarbazine for intra-abdominal and paraspinal EBV-SMTs. The patient



**Figure 5.** Epstein-Barr virus in situ hybridization (40× magnification).

started chemotherapy in October 2003, and was alive with disease without progression 5 years later.<sup>11</sup>

Post-transplantation patients with EBV-SMTs can exhibit improvement after reduction in immunosuppressive therapy.<sup>3</sup> In some cases, the addition of antiviral therapy has yielded good results. The mechanism of action of antiviral drugs on predominantly latent EBV tumors remains unclear.<sup>5</sup> A case report by Bonatti and colleagues described a 23-year-old patient who developed multifocal EBV-SMTs after a heart transplant who was switched from cyclosporine to sirolimus. Afterward, antiviral therapy with acyclovir and gancyclovir was initiated, followed by maintenance therapy with famcyclovir and surgical resection, which resulted in long-term survival.<sup>14</sup>

Changing immunosuppressive therapy to sirolimus has produced encouraging outcomes in some post-transplantation patients with EBV-SMTs. In a case report of a 55-year-old woman with recurrent EBV-SMT of the liver after renal transplantation, complete tumor regression was observed after cyclosporine was discontinued and

replaced with sirolimus therapy.<sup>13</sup> Sirolimus may have antitumor benefits in addition to its immunosuppressive properties. Sirolimus acts on the mammalian target of rapamycin-associated protein located downstream from the PI3K-AKT tumor survival pathway and can effectively induce cell-cycle arrest in cells with high AKT activity, such as EBV tumors.<sup>13,15</sup> EBV cells show moderate staining for mTOR and AKT, and sensitivity to sirolimus is known to closely correlate with AKT activity levels.<sup>13</sup> The antitumor activity of sirolimus may also involve the impaired production of vascular endothelial growth factor and inhibition of angiogenesis, which has been demonstrated in mice.<sup>15</sup> However, there are no reports of the use of sirolimus in HIV/AIDS patients with EBV-SMTs.

## Conclusion

EBV-SMTs are rare neoplasms in adults and are seen in immunocompromised patients. They are slow growing, locally invasive tumors that do not usually show a significant metastatic potential; however, they can have multicentric sites of origin. Local surgical resection is often curative, as was the case in our patient. In AIDS patients, optimizing HAART may also be clinically beneficial. Chemotherapy and radiotherapy may be useful in unresectable tumors. In post-transplantation patients with EBV-SMTs, decreasing immunosuppression, substituting sirolimus, and incorporating antiviral drugs that suppress EBV have improved disease control and may lead to better outcomes.

## References

1. Perrine SP, Hermine O, Small T, et al. A phase 1/2 trial of arginine butyrate and ganciclovir in patients with Epstein-Barr virus-associated lymphoid malignancies. *Blood*. 2007;109:2571-2578.
2. Boman F, Gultekin H, Dickman PS. Latent Epstein-Barr virus infection demonstrated in low-grade leiomyosarcomas of adults with acquired immunodeficiency syndrome, but not in adjacent Kaposi's lesion or smooth muscle tumors in immunocompetent patients. *Arch Pathol Lab Med*. 1997;121:834-838.
3. Gallien S, Zuber B, Polivka M, et al. Multifocal Epstein-Barr virus-associated smooth muscle tumor in adults with AIDS: case report and review of the literature. *Oncology*. 2008;74:167-176.
4. Jenson HB, Montalvo EA, McClain KL, et al. Characterization of natural Epstein-Barr virus infection and replication in smooth muscle cells from a leiomyosarcoma. *J Med Virol*. 1999;57:36-46.
5. Rogatsch H, Bonatti H, Menet A, et al. Epstein-Barr virus-associated multicentric leiomyosarcoma in an adult patient after heart transplantation: case report and review of the literature. *Am J Surg Pathol*. 2000;24:614-621.
6. Suankratay C, Shuangshoti S, Mutirangura A, et al. Epstein-Barr virus infection-associated smooth-muscle tumors in patients with AIDS. *Clin Infect Dis*. 2005;40:1521-1528.
7. Deyrup AT, Lee VK, Hill CE, et al. Epstein-Barr virus-associated smooth muscle tumors are distinctive mesenchymal tumors reflecting multiple infection events: a clinicopathologic and molecular analysis of 29 tumors from 19 patients. *Am J Surg Pathol*. 2006;30:75-82.
8. Deyrup AT. Epstein-Barr virus-associated epithelial and mesenchymal neoplasms. *Hum Pathol*. 2008;39:473-483.
9. Khunamornpong S, Sukpan K, Suprasert P, et al. Epstein-Barr virus-associated smooth muscle tumor presenting as a vulvar mass in an acquired immunodeficiency syndrome patient: a case report. *Int J Gynecol Cancer*. 2007;17:1333-1337.

10. Piriou ER, Van Dort K, Nanlohy NM, et al. Altered EBV viral load setpoint after HIV seroconversion is in accordance with lack of predictive value of EBV load for the occurrence of AIDS-related non-Hodgkin lymphoma. *J Immunol*. 2004;172:6931-6937.
11. Moore Dalal K, Antonescu CR, DeMatteo RP, et al. EBV-associated smooth muscle neoplasms: solid tumors arising in the presence of immunosuppression and autoimmune diseases. *Sarcoma*. 2008;2008: 859407.
12. Piriou ER, Jansen CA, Van Dort K, et al. Reconstitution of EBV latent but not lytic antigen-specific CD4<sup>+</sup> and CD8<sup>+</sup> T cells after HIV treatment with highly active antiretroviral therapy. *J Immunol*. 2005;175:2010-2017.
13. Toh HC, Teo M, Ong KW, et al. Use of sirolimus for Epstein-Barr virus-positive smooth-muscle tumour. *Lancet Oncol*. 2006;7:955-957.
14. Bonatti H, Hoefler D, Rogatsch H, et al. Successful management of recurrent Epstein-Barr virus-associated multilocal leiomyosarcoma after cardiac transplantation. *Transplant Proc*. 2005;37:1839-1844.
15. Stallone G, Schena A, Infante B, et al. Sirolimus for Kaposi's sarcoma in renal-transplant recipients. *N Engl J Med*. 2005;352:1317-1323.

# Review

## Epstein-Barr Virus–Associated Smooth Muscle Tumors

Hal B. Jenson, MD

Baystate Medical Center, Tufts University School of Medicine,  
Springfield, Massachusetts

Cela and colleagues<sup>1</sup> describe an interesting case of a 66-year-old man with HIV infection and AIDS who developed a malignant smooth muscle tumor (SMT), or leiomyosarcoma, associated with Epstein-Barr virus (EBV). Cure was achieved by surgical excision. The diagnosis and clinical management of this case underscore the nuances of these rare tumors.

In the milieu of the emergence of HIV and AIDS, several interesting and important new clinical entities were recognized. Among patients with AIDS, primary EBV infection as well as uncontrolled replication of latent EBV was recognized as the cause of AIDS-associated comorbidities, including oral hairy leukoplakia and lymphoid interstitial pneumonitis, the latter occurring primarily among children. In addition, patients with AIDS were recognized to be at increased risk of certain cancers that are causally associated with specific

Address correspondence to:

Hal B. Jenson, MD, Division of Academic Affairs, Baystate Medical Center, 759 Chestnut Street, Springfield, MA 01199; Phone: 413-794-5588; Fax: 413-794-3000; E-mail: hal.jenson@tufts.edu.

viral infections. These cancers include non-Hodgkin lymphoma with EBV; Kaposi sarcoma with Kaposi sarcoma-associated herpesvirus (KSHV), also known as human herpesvirus type 8 (HHV8); hepatocellular carcinoma with hepatitis B and C viruses; cervical cancer with human papillomaviruses, especially types 16 and 18 among other oncogenic types; and squamous cell carcinoma of the skin with human papillomaviruses, especially types 5 and 8.

### Discovery of EBV-associated SMTs

A new virus association with cancer was also identified in the 1990s—that of EBV with leiomyosarcomas (or SMT).<sup>2</sup> These tumors were reported rarely before 1985. From 1985–1990, 5 cases were reported of SMTs associated with HIV/AIDS, all among children. From 1991–1994, 11 additional cases were reported. Concurrently, SMTs were being reported among patients following kidney or liver organ transplantation, with approximately one-third of these cases among children. Definitive histopathologic criteria defining benign (leiomyoma) and malignant (leiomyosarcoma) smooth muscle tumors are not well established. The uncertainty between benign and malignant smooth tumors has resulted in many reported cases of “smooth muscle tumors” that are not further classified.

The identification of EBV infection of smooth muscle cells of leiomyosarcoma was reported first in an adult with HIV/AIDS in 1994<sup>3</sup> and in 2 series published together in early 1995 of 6 persons with HIV/AIDS<sup>4</sup> and 3 organ transplant recipients.<sup>5</sup> These initial reports have been substantiated by numerous additional reports of cases of EBV-associated SMTs in immunocompromised children and adults, including the case by Cela and colleagues.<sup>1</sup> EBV-associated SMTs have been consistently associated with underlying immunodeficiency, whether resulting from HIV/AIDS, post-transplantation immunosuppression, or congenital immunodeficiency. EBV has not been found in smooth muscle cells from healthy individuals, nor has it been seen in SMTs in the absence of an underlying immunocompromising condition.

### Pathogenesis of EBV-associated SMTs

A key finding using *in situ* hybridization for EBV-encoded RNAs (EBER) is that EBV is present in more than 90% of the smooth muscle cells of the SMTs in immunocompromised persons, but not in adjacent normal tissues and not in SMTs of immunocompetent persons (see Figure 5 of the report by Cela and colleagues<sup>1</sup>). In a series of 7 smooth muscle cell tumors from 4 patients with HIV/AIDS near or at the time of tumor diagnosis, semi-

quantitative EBV levels ranged from 170,442–659,668 EBV copies per 100,000 cells, with an average of 451,140 copies per 100,000 cells. If all cells are uniformly infected with EBV, as indicated by the uniform staining for EBER by *in situ* hybridization, this equates to an average of 4.5 EBV genome copies per cell,<sup>6</sup> consistent with the amounts of EBV in lymphoblastoid cell lines, which characteristically have 10 or fewer episomes per cell. These results are consistent with the semi-quantitative levels of EBV reported in SMTs from patients following organ transplantation.<sup>5</sup> These cases also show high levels of cell-free EBV in peripheral blood, as reported in the case by Cela and colleagues, with 20,050 EBV copies/mL.<sup>1</sup> Taken together, the presence of EBV in all tumor cells, the high copy numbers of EBV in the tumor cells, and the high levels of circulating EBV confirm very high levels of EBV replication with these tumors.

The development of EBV-associated SMTs appears to be limited to the milieu of immunodeficiency, which may be congenital (eg, common variable immunodeficiency, ataxia-telangiectasia) or acquired (eg, HIV/AIDS, immunosuppressive therapy following organ transplantation).

The sequence of events in the transformation from normal smooth muscle cells to EBV-infected leiomyosarcomatous cells appears to begin with EBV infection of the muscle cells prior to malignant transformation. This is supported by the finding of EBV monoclonality of leiomyosarcomas,<sup>4,6</sup> even in individuals with multiple tumors, which are common among immunocompromised persons who develop leiomyosarcoma. One example is that of a 5-year-old girl with 2 separate tumors taken at different times and from different sites, with each tumor demonstrating a different EBV monoclonality, confirming that these 2 tumors developed independently.<sup>4</sup> The presence of EBV in both a leiomyoma and leiomyosarcoma occurring in an 8-year-old girl suggests that EBV infects the smooth muscle cells before they undergo malignant transformation, and thus plays a pivotal role in the progression to malignancy.<sup>4</sup> Viral integration into the cell genome that might account for malignant transformation has not been found. It appears that the principal factor that predisposes to leiomyosarcoma—impaired host immunity—facilitates the simultaneous development of multiple primary tumors.

The EBV receptor (CD21, also known as CR2), which is also the receptor for the C3d component of complement, is found on smooth muscle cells at relatively higher levels on the cells of both leiomyomas and leiomyosarcomas from persons with HIV/AIDS and at lower levels in tumors from HIV-uninfected patients.<sup>4,6</sup> This finding suggests that entry of EBV into muscle cells is directly or indirectly influenced by the immunosuppression resulting

from HIV/AIDS. This emphasizes the important role of immunity, which normally controls circulating EBV levels, and may target EBV-infected smooth muscle cells if such infection should occasionally occur.

Most solitary EBV-associated tumors are best managed by surgical excision, as in the case reported by Cela and colleagues.<sup>1</sup> An alternate approach that may be necessary for multifocal tumors that cannot be resected is to ameliorate the immunosuppressive state, again underscoring the critical role of the immune system in tumor development. Post-transplant immunosuppressive therapy should be modified to reduce the immunosuppression,<sup>7</sup> and highly active antiretroviral therapy should be optimized for patients with HIV/AIDS.<sup>8</sup>

## Conclusion

EBV is recognized chiefly as a lymphotropic virus, infecting primarily B lymphocytes, as well as T lymphocytes of some T-cell malignancies. That EBV infection of smooth muscle cells even occurred was a surprising and unexpected discovery. These EBV-associated SMTs provide clear and consistent evidence of the ability of EBV to infect smooth muscle cells, although with a prerequisite of immune deficiency, and therefore EBV should also be recognized as a leiomyotropic virus.

Leiomyosarcomas expand the spectrum of EBV-associated malignancies, and also of malignancies associated

with impaired immunity. Underlying immune deficiency is a critical factor that facilitates EBV infection of smooth muscle cells, which is followed by malignant transformation and proliferation. The tumors themselves have low propensity for local invasion and metastasis. Excision is the best option for solitary tumors, and amelioration of the underlying immune deficiency is recommended for multifocal and unresectable tumors.

## References

1. Cela I, Shah NB, Bradly D, Loew J, Leslie W. An Epstein-Barr virus-associated smooth muscle tumor successfully treated with surgical resection. *Clin Adv Hematol Oncol*. 2010;8:423-426.
2. Jenson HB. Leiomyosarcoma. In: Tselis AC, Jenson HB, eds. *Epstein-Barr Virus*. New York, NY: Taylor & Francis; 2006:297-309.
3. Prévot S, Nérès J, de Saint Maur PP. Detection of Epstein Barr virus in an hepatic leiomyomatous neoplasm in an adult human immunodeficiency virus 1-infected patient. *Virchows Archiv*. 1994;425:321-325.
4. McClain KL, Leach CT, Jenson HB, et al. Association of Epstein-Barr virus with leiomyosarcomas in young people with AIDS. *N Engl J Med*. 1995;332:12-18.
5. Lee ES, Locker J, Nalesnik M, et al. The association of Epstein-Barr virus with smooth-muscle tumors occurring after organ transplantation. *N Engl J Med*. 1995;332:19-25.
6. Jenson HB, Leach CT, McClain KL, et al. Benign and malignant smooth muscle tumors containing Epstein-Barr virus in children with AIDS. *Leuk Lymphoma*. 1997;27:303-314.
7. Bonatti H, Hoefler D, Rogatsch H, Margreiter R, Larcher C, Autretter H. Successful management of recurrent Epstein-Barr virus—associated multilocal leiomyosarcoma after cardiac transplantation. *Transplant Proc*. 2005;37:1839-1844.
8. Suankratay C, Shuangshoti S, Mutirangura A, et al. Epstein-Barr virus infection-associated smooth-muscle tumors in patients with AIDS. *Clin Infect Dis*. 2005;40:1521-1528.