

ADVANCES IN LLM

Current Developments in the Management of Leukemia, Lymphoma, and Myeloma

Section Editor: Susan O'Brien, MD

Advances in the Management of Primary Mediastinal Large B-Cell Lymphoma



Ranjana H. Advani, MD
Saul A. Rosenberg Professor of Lymphoma
Stanford Cancer Institute
Stanford, California

H&O What is primary mediastinal large B-cell lymphoma?

RA Primary mediastinal large B-cell lymphoma is a subtype of diffuse large B-cell lymphoma that is more common in younger women. The disease typically presents with a bulky mediastinal mass and can be associated with pleural and pericardial effusions. Most patients are diagnosed with early-stage disease, and approximately 20% present with stage 3 or 4 disease, which can involve the kidneys and adrenal glands.

Expression of CD30 is more common in primary mediastinal large B-cell lymphoma than in other types of large B-cell lymphoma, and at the molecular level, alterations are seen in the Janus kinase/signal transducers and activators of transcription (JAK-STAT) pathway.

H&O What is the prognosis?

RA Overall, the prognosis is good, with a high response rate. Approximately 90% of patients are cured with contemporary therapies. Prognostic factors are the same as those used for large-cell lymphoma, and the International Prognostic Index (IPI) is used to predict prognosis. Patients with a high IPI tend to have a worse outcome than those with a low IPI.

H&O How is primary mediastinal large B-cell lymphoma diagnosed and distinguished from other lymphomas?

RA The diagnosis is based on clinical and pathologic correlation. The clinical presentation is primarily a large

mediastinal mass, which must be biopsied to distinguish it from Hodgkin lymphoma and other types of lymphoma. The mass tends to have a fair amount of sclerosis, and it is important to obtain an adequate sample size so that the pathologist can perform the necessary immunohistochemistry stains and other tests.

H&O Are there particular management challenges?

RA The mediastinal mass can be associated with superior vena cava syndrome and pleural effusions. Patients can be fairly symptomatic, so they often need to start treatment relatively quickly. The traditional approach

Researchers in the field are excited about the role of checkpoint inhibitors in patients with primary mediastinal large B-cell lymphoma.

to management has been combined-modality therapy consisting of rituximab (Rituxan, Genentech/Biogen) given with chemotherapy, such as cyclophosphamide, doxorubicin, vincristine, and prednisone (CHOP) or

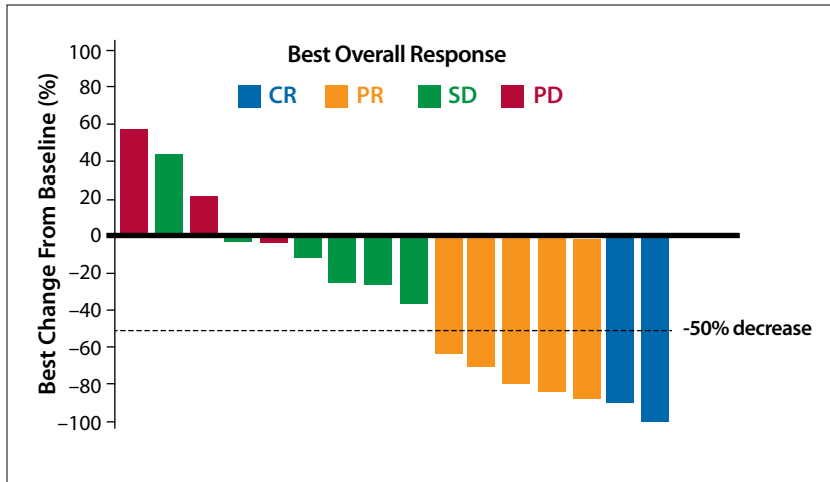


Figure. Best overall response among patients in a phase 1b trial of pembrolizumab in patients with relapsed/refractory primary mediastinal large B-cell lymphoma. CR, complete response; PD, progressive disease; PR, partial response; SD, stable disease. Adapted from Zinzani PL et al. *Blood*. 2017;130(3):267-270.

etoposide, leucovorin, doxorubicin, cyclophosphamide, vincristine, prednisone, and bleomycin (VACOP-B), followed by radiotherapy. Since patients are often young and female, therapy is evolving in order to avoid potential long-term side effects related to radiotherapy. This has led to the adoption of a chemotherapy-alone approach using dose-adjusted rituximab plus etoposide, doxorubicin, cyclophosphamide, vincristine and prednisone (DA-EPOCH-R), with excellent results.

H&O What are the unmet needs?

RA When patients relapse or are refractory to combined modality therapy or an intense regimen such as DA-EPOCH-R, standard salvage approaches are often ineffective, and represent an unmet need.

H&O Are there novel agents in clinical trials?

RA Researchers in the field are excited about the role of checkpoint inhibitors in patients with primary mediastinal large B-cell lymphoma. Zinzani and colleagues recently reported encouraging results from a phase 1b trial evaluating pembrolizumab (Keytruda, Merck) in patients with relapsed/refractory primary mediastinal large B-cell lymphoma. Among 17 patients, the overall response rate was 41% (Figure). Six additional patients (35%) had stable disease.

H&O Can biomarkers be used to assess treatment?

RA Currently, there are no biomarkers. There are emerging data on the use of circulating tumor DNA to monitor minimal residual disease or to detect early relapse. Further research is needed.

H&O Are there any other promising areas of research?

RA In Europe, combined-modality therapy is still used frequently, more so than in the United States. An area of ongoing research is whether patients who have achieved a metabolic complete remission according to positron emission tomography/computed tomography criteria can avoid radiotherapy after chemotherapy.

The role of checkpoint inhibitors is another important area of research. Given the effectiveness of these agents in relapsed disease, utility in the frontline setting will need to be evaluated.

Disclosure

Dr Advani has received institutional research funding from Genentech/Roche and from Merck for participation in an advisory board.

Suggested Readings

Binkley MS, Hiniker SM, Wu S, et al. A single-institution retrospective analysis of outcomes for stage I-II primary mediastinal large B-cell lymphoma treated with immunochemotherapy with or without radiotherapy. *Leuk Lymphoma*. 2016;57(3):604-608.

Broccoli A, Casadei B, Stefoni V, et al. The treatment of primary mediastinal large B-cell lymphoma: a two decades monocentric experience with 98 patients [published online April 17, 2017]. *BMC Cancer*. 2017;17(1):276. doi: 10.1186/s12885-017-3269-6.

Dunleavy K, Pittaluga S, Maeda LS, et al. Dose-adjusted EPOCH-rituximab therapy in primary mediastinal B-cell lymphoma. *N Engl J Med*. 2013;368(15):1408-1416.

Steidl C, Gascoyne RD. The molecular pathogenesis of primary mediastinal large B-cell lymphoma. *Blood*. 2011;118(10):2659-2669.

Zinzani PL, Ribrag V, Moskowitz CH, et al. Safety and tolerability of pembrolizumab in patients with relapsed/refractory primary mediastinal large B-cell lymphoma. *Blood*. 2017;130(3):267-270.